# Anatomia radiologiczna raka przełyku, raka żołądka i raka trzustki z uwzględnieniem grup węzłowych

Joanna Socha

# ANATOMIA RADIOLOGICZNA dla radioterapeuty:

## PRZEŁYK, EGJ

- **CTV „węzłowy”**
  **Które stacje węzłowe ma obejmować?**
  **W jaki sposób je wyznaczać?**
- sugerowany zakres nCTV, przykładowy nCTV
  - przełyk
    - szyjny
    - piersiowy górny, dolny, środkowy
  - EGJ

## ŻOŁĄDEK, TRZUSTKA

**CTV w radioterapii pooperacyjnej** – na co zwrócić uwagę?

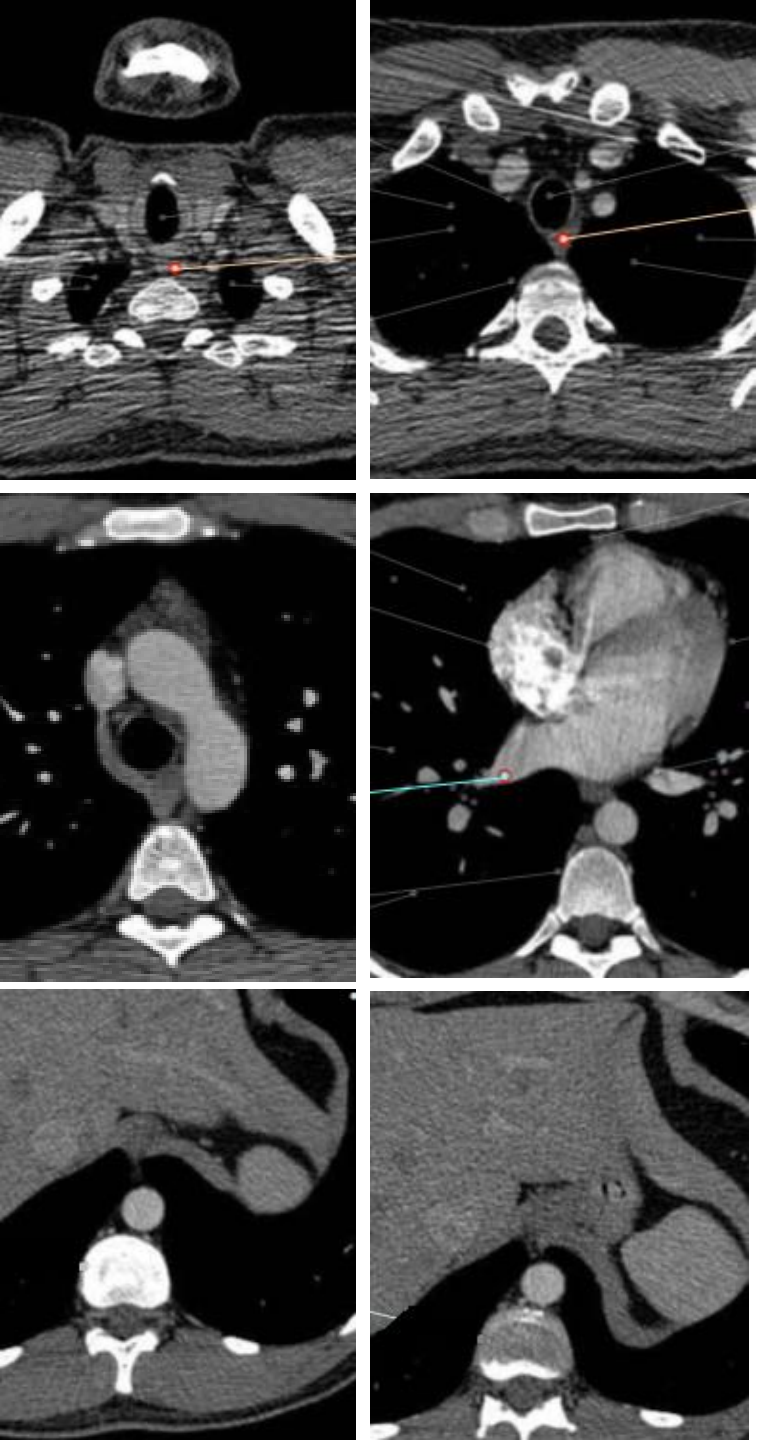

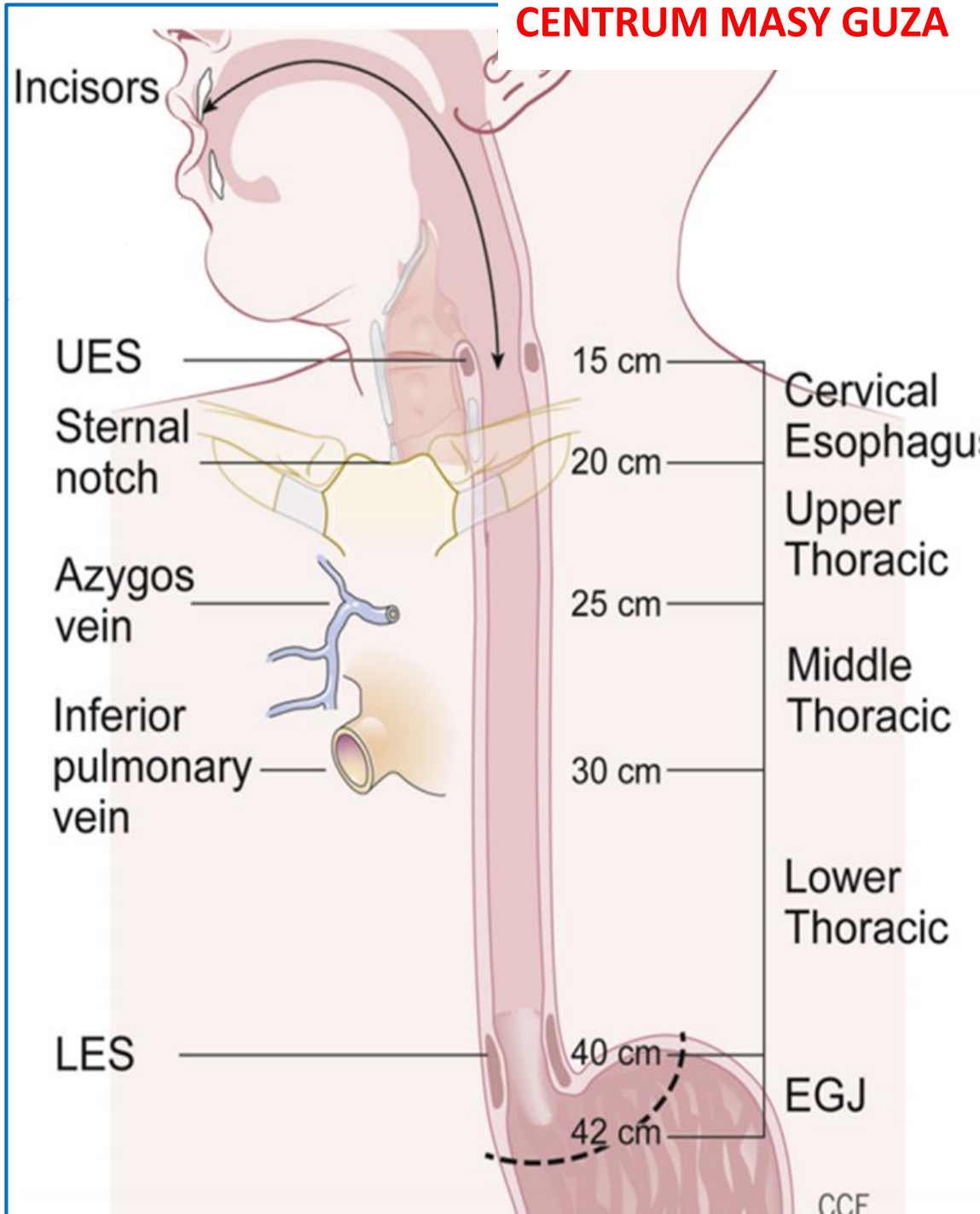
CENTRUM MASY GUZA
Incisors
UES
Sternal notch
Azygos vein
Inferior pulmonary vein
LES
15 cm
20 cm
25 cm
30 cm
40 cm
42 cm
Cervical Esophagus
Upper Thoracic
Middle Thoracic
Lower Thoracic
EGJ
CCF

# CTV „węzłowy” – **szyjny odcinek przełyku**

Zakres:

- szyja: III, IVAiB, VIB /deVoorde R&O 2014; Hirano 2007; Cao 2015/
  - ryzyko zajęcia gr. II/III 43%, gr.IV 38%! /Hirano 2007/
- klp: 2RiL, 3AiP, 4 RiL /deVoorde R&O 2014 /

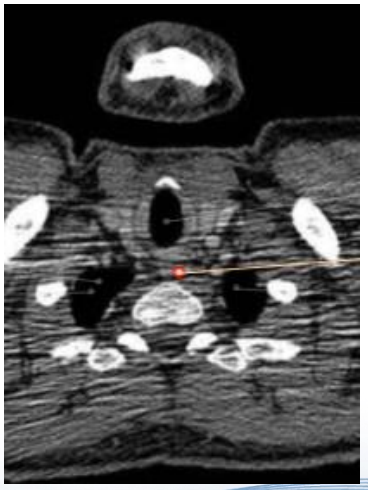

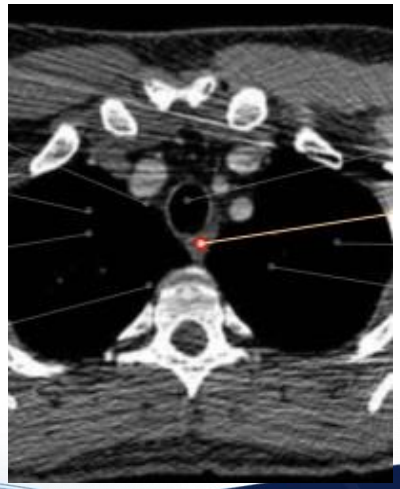

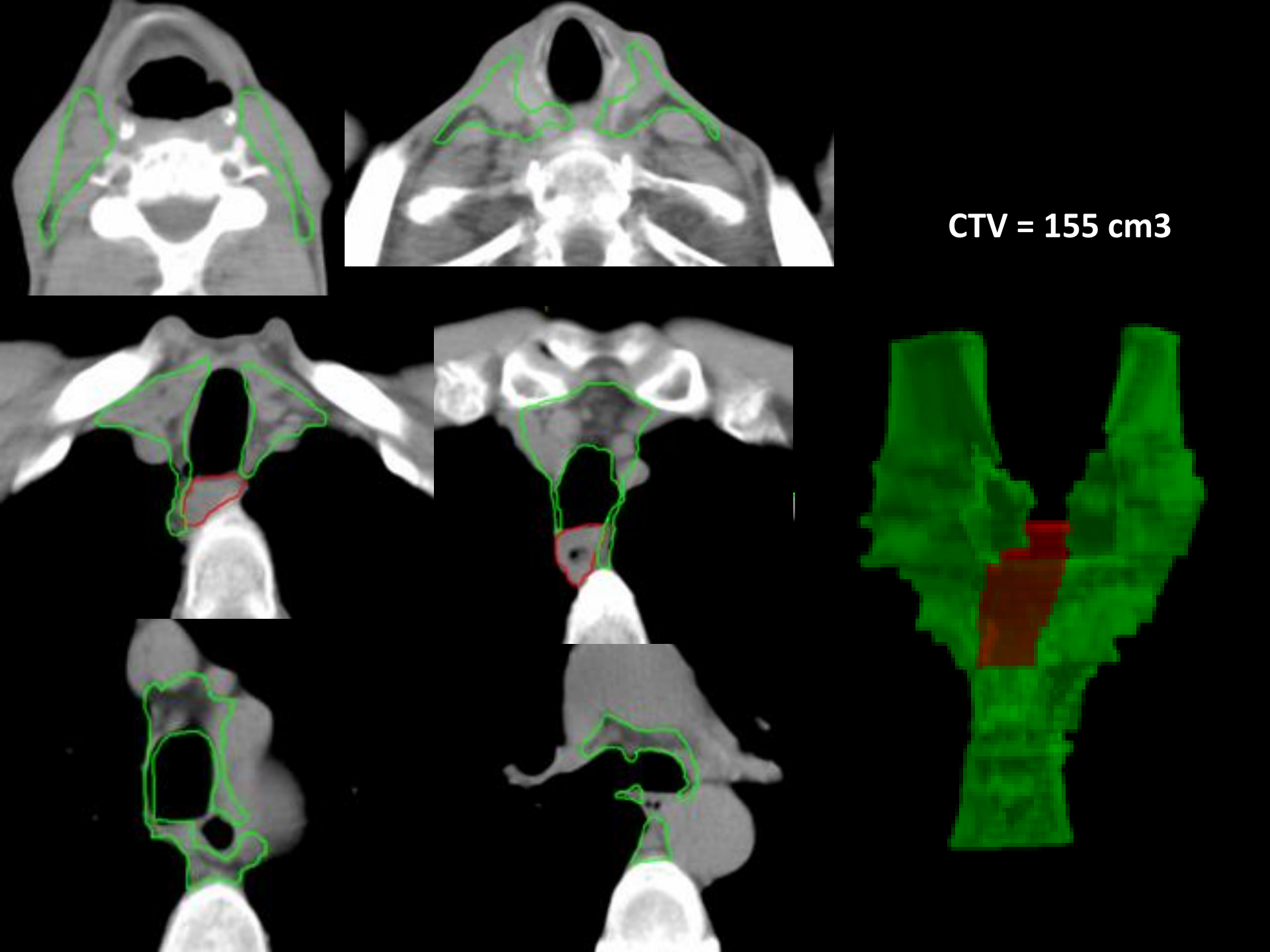
CTV = 155 cm3

## GÓRNA GRANICA CTV = GÓRNA GRANICA GR.III – KOŚĆ GNYKOWA

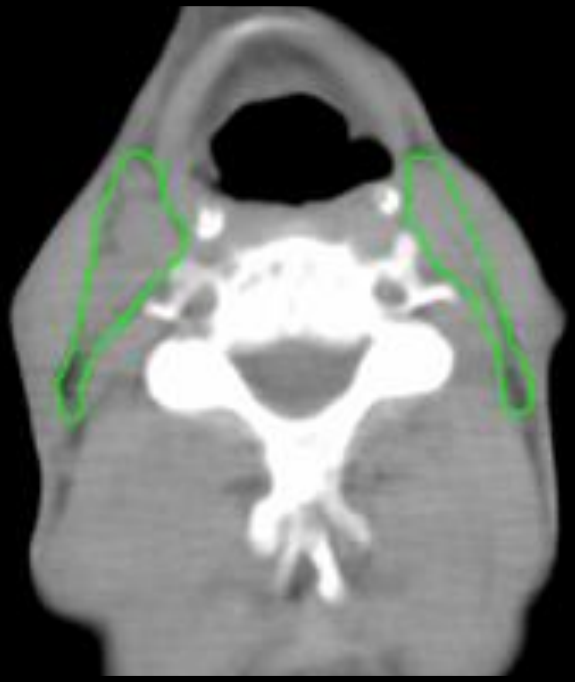

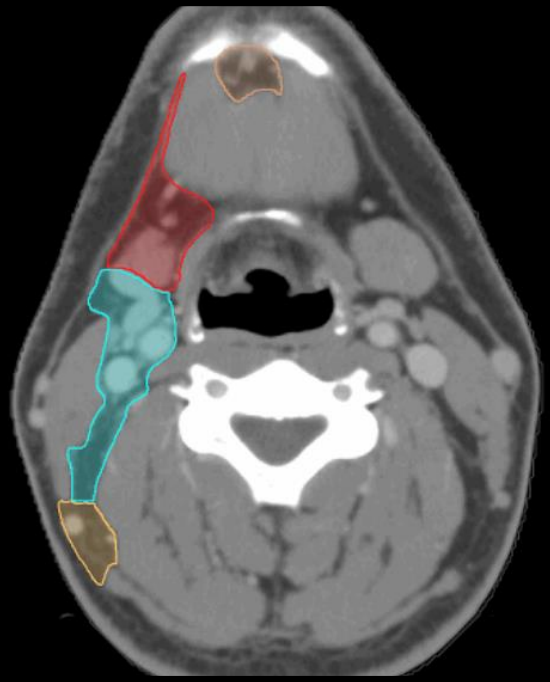

## Ch. pierścieniowata = ostatni slajd z gr.III + gr. VIB – od dolnego brzegu chrz. tarczowatej

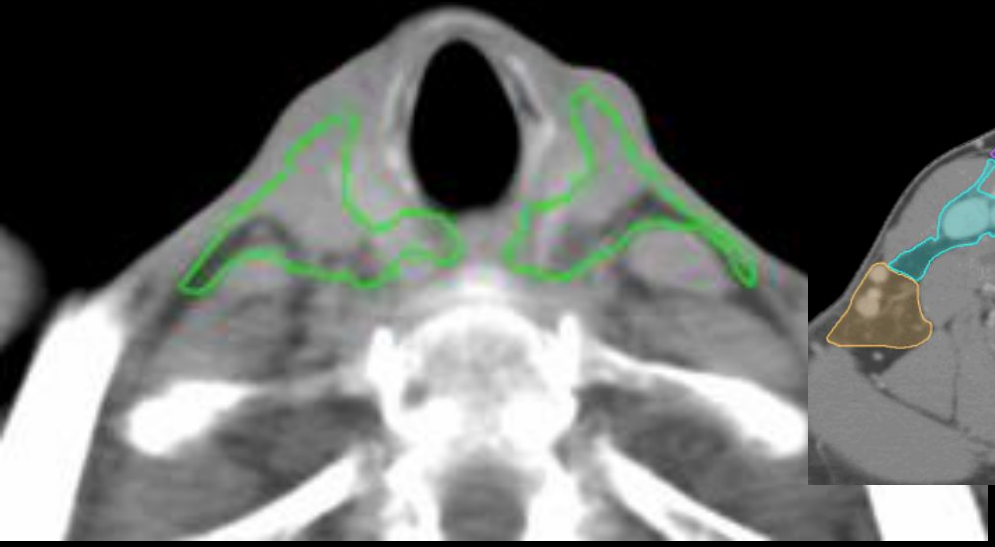

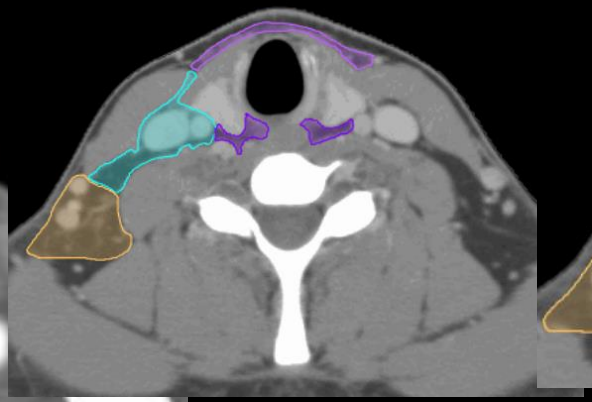

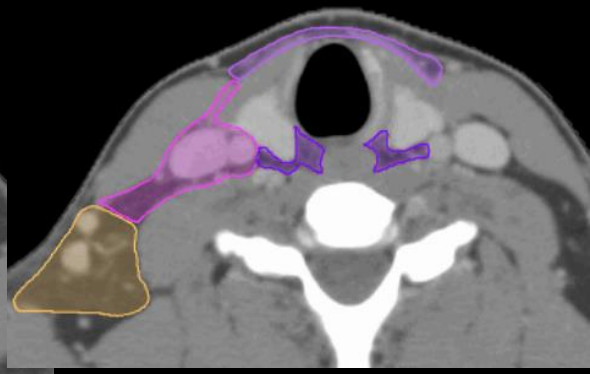

Gregoire, R&O 2014

# Nad wcięciem mostka: gr. IVA → IVB. nadal gr. VIB

Luo, 2017

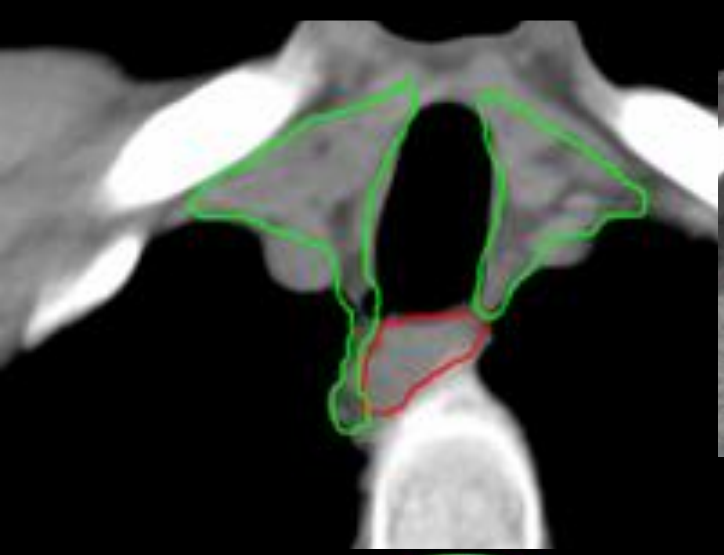

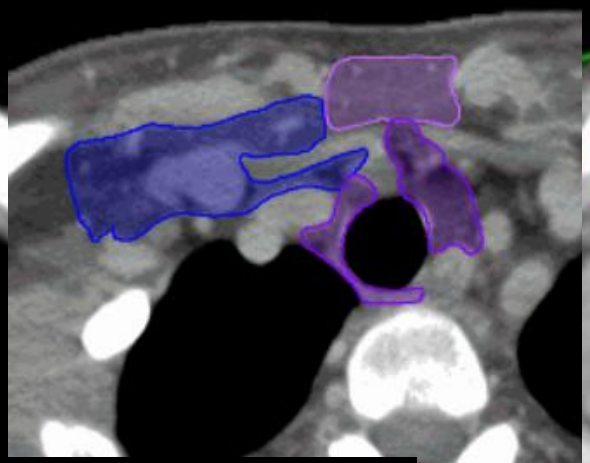

Gregoire, R&0 2014

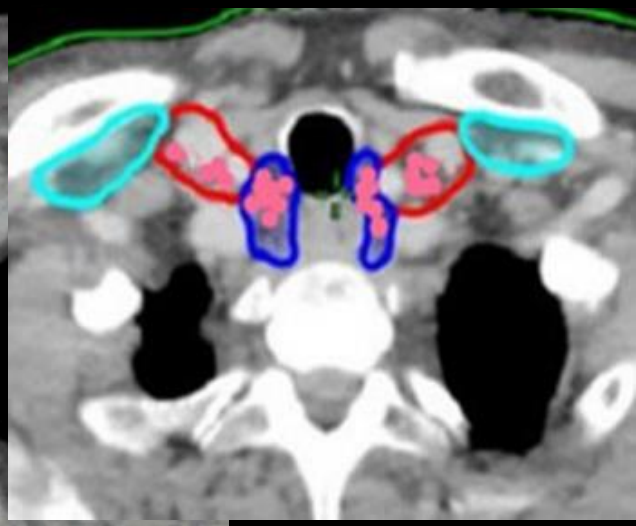

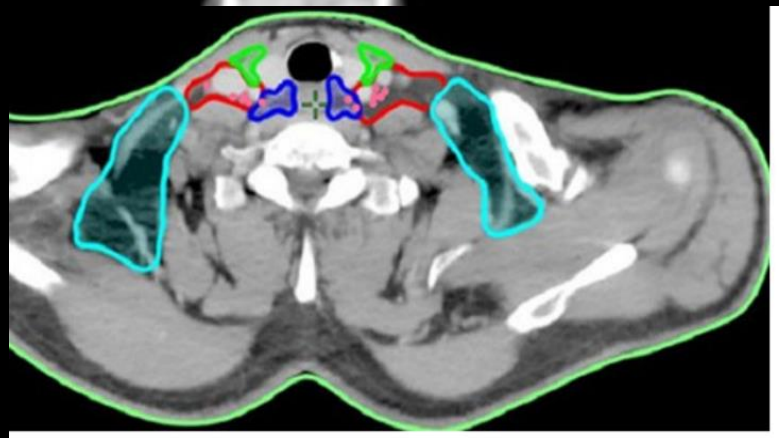

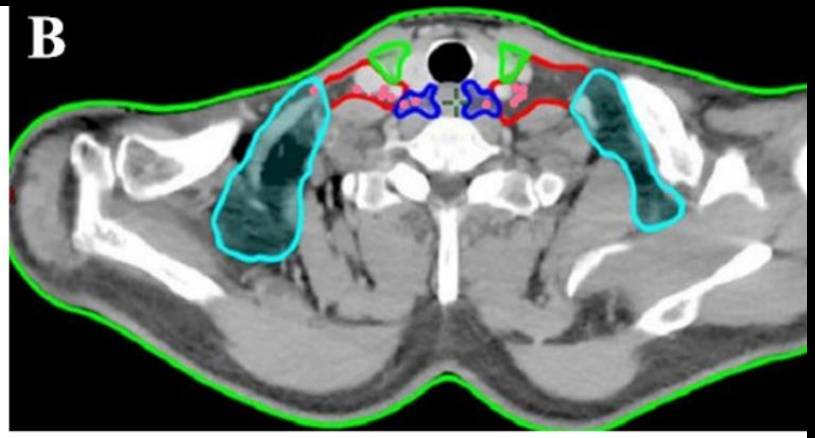


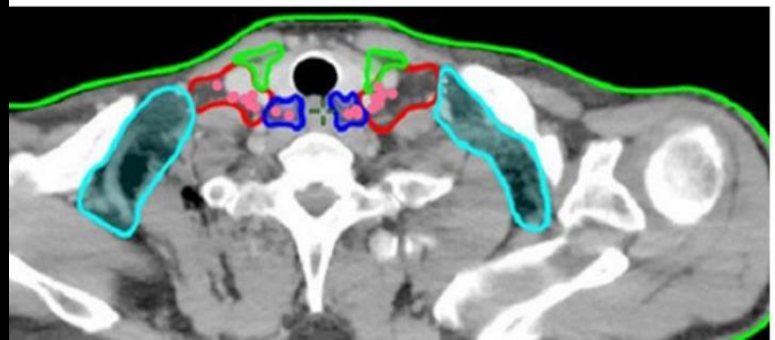

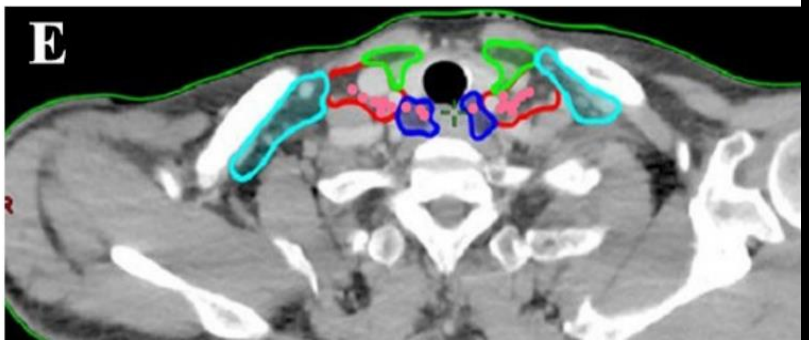


Luo, 2017

## Wcięcie mostka: gr. 2 RiL, 3P (i 3A ~ dawna gr. VII ww. chł. szyi - zamostkowe)

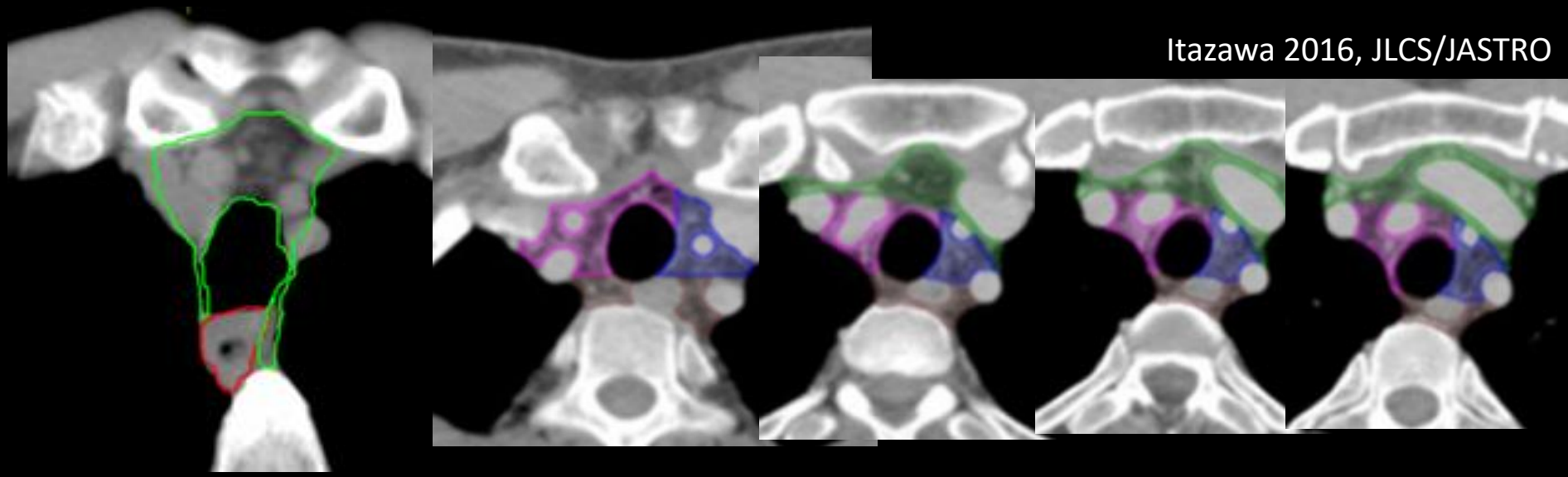

Itazawa 2016, JLCS/JASTRO

## Łuk aorty: gr. 4 RiL, 3P

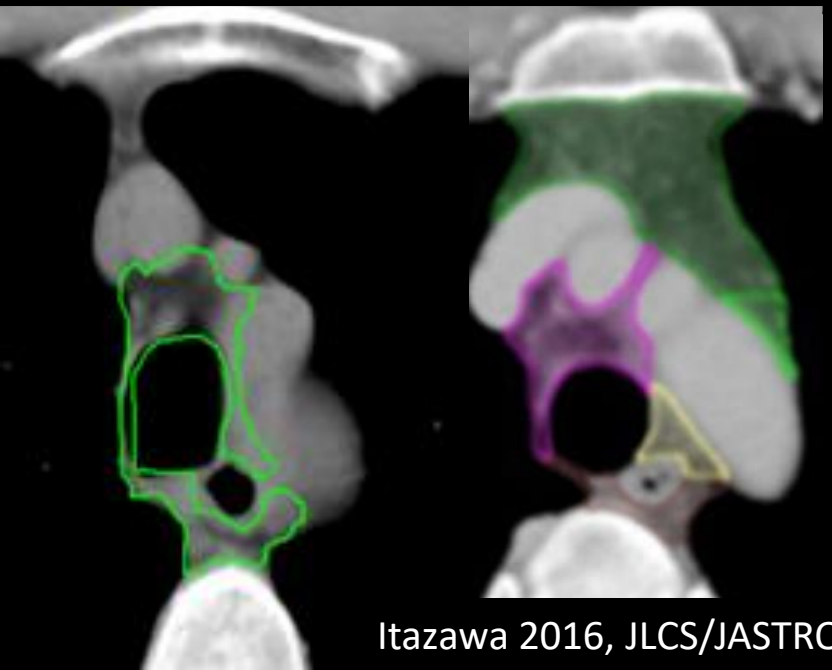

Itazawa 2016, JLCS/JASTRO

## Dolna granica CTV – ostatni slajd nad cariną; 4RiL, 3P

Chapet, IJROBP2005

# CTV „węzłowy” – **odcinek piersiowy GÓRNY**

Zakres:

- szyja: gr. IVAiB, VIB /Wu, IJROBP 2014/
- klp: 2R i L, 3P, 4 R i L , 7, 8

/Huang, R&O 2015/

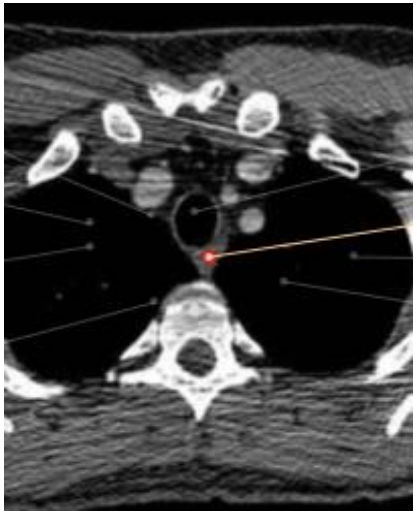

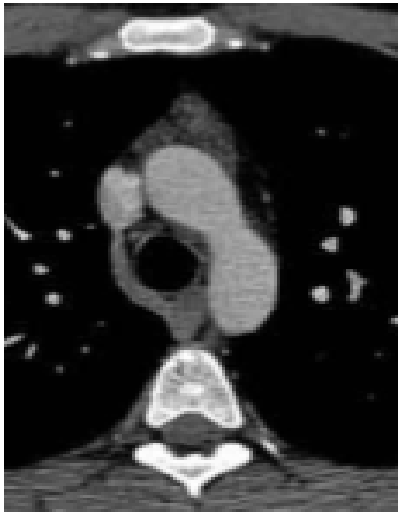

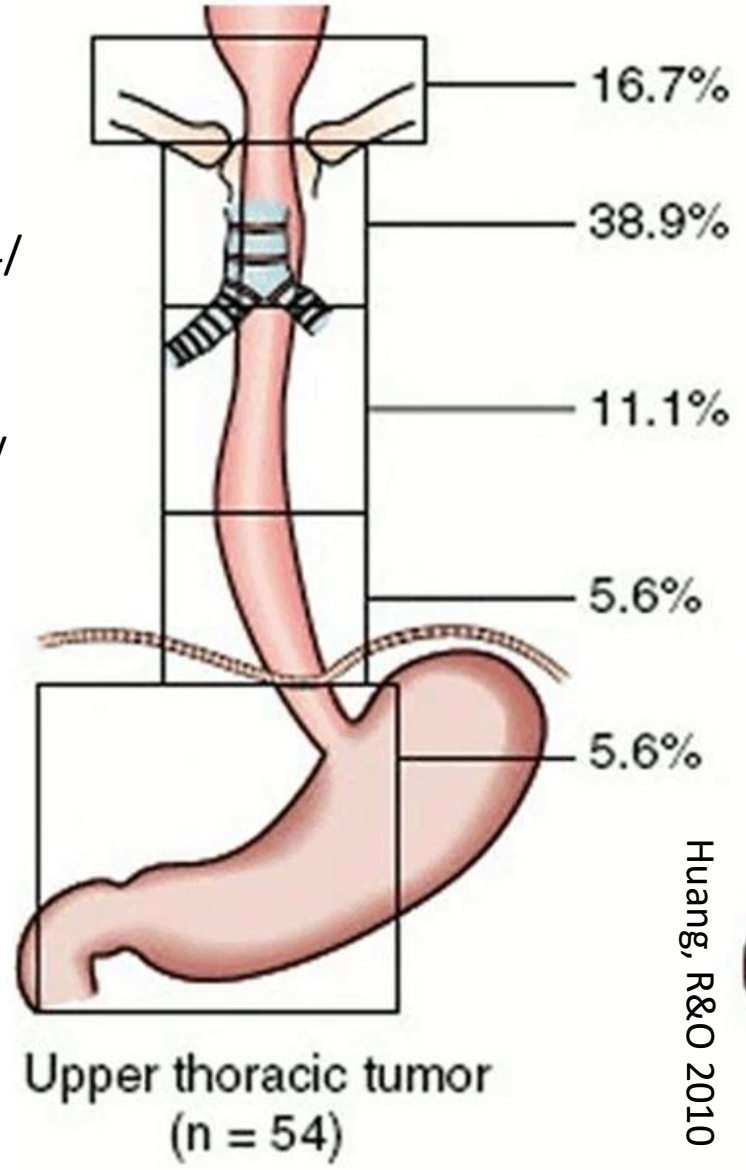


Huang, R&O 2010

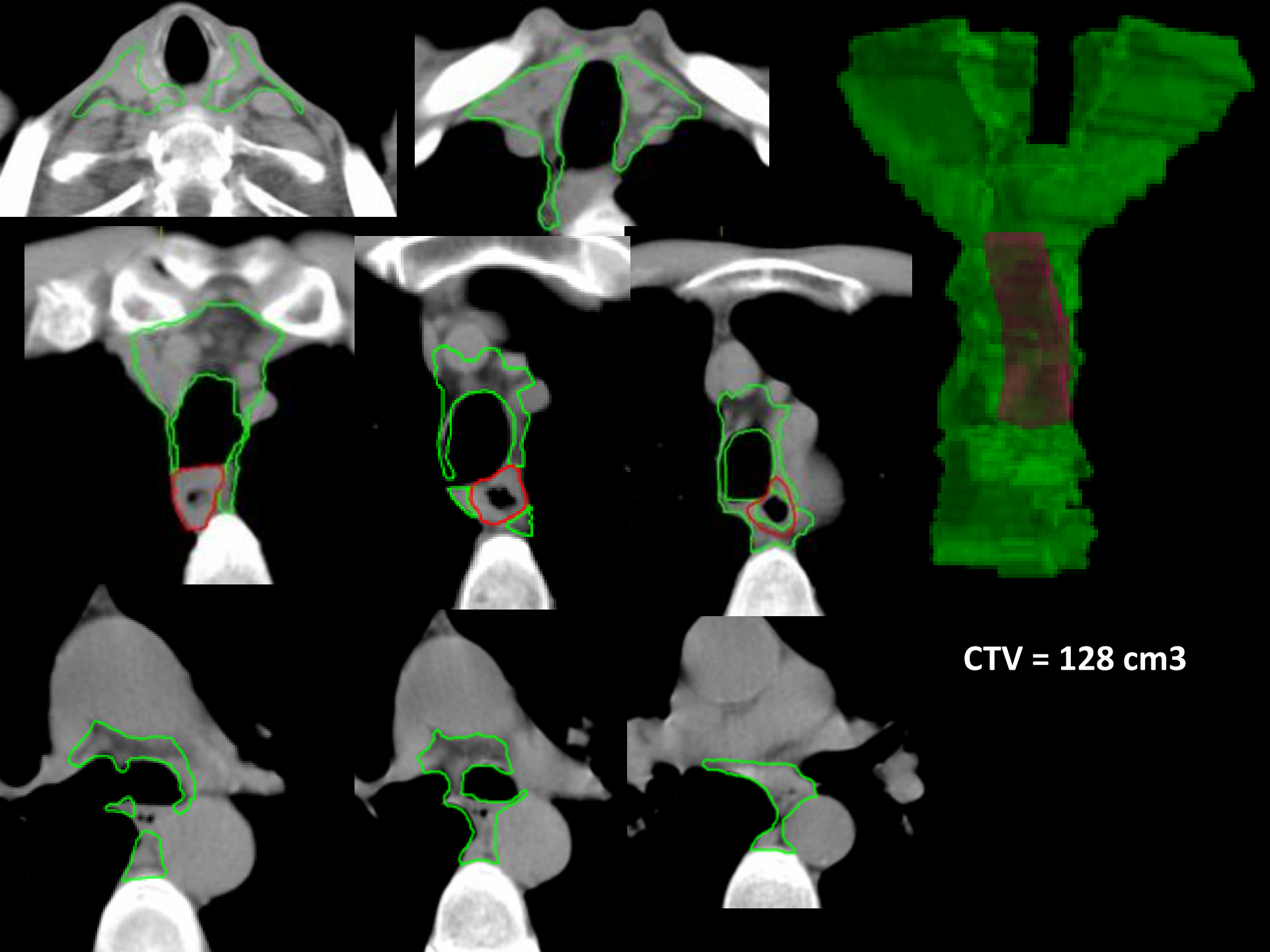
CTV = 128 cm3

## Górna gr. CTV: gr. IVA i VIB – dolny brzeg chrząstki pierścieniowatej

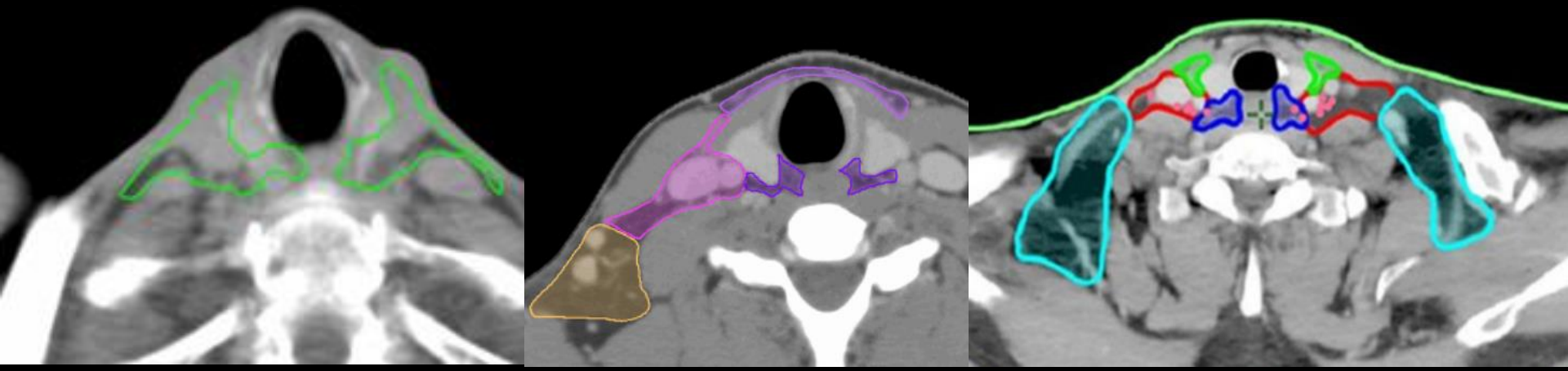

Gregoire, R&0 2014

## Nad cariną: 4RiL, 3P

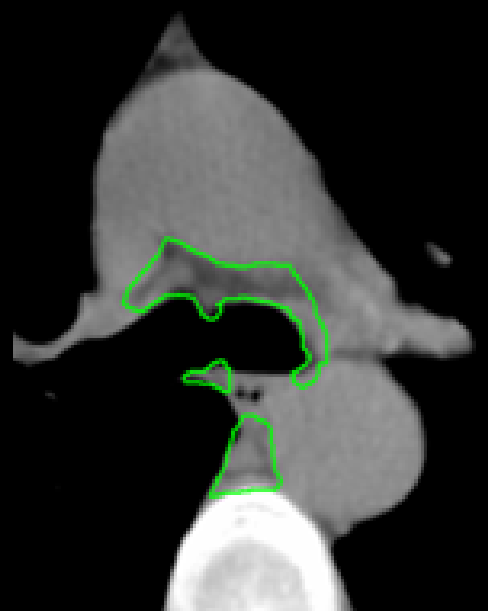

## Carina: jeszcze 4RiL, 7, 3P → 8

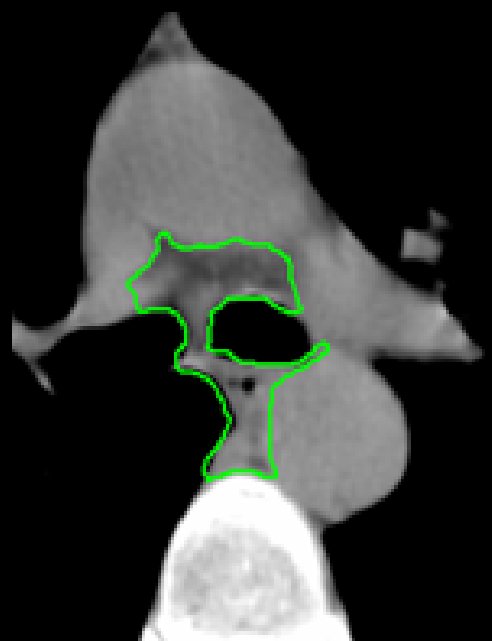

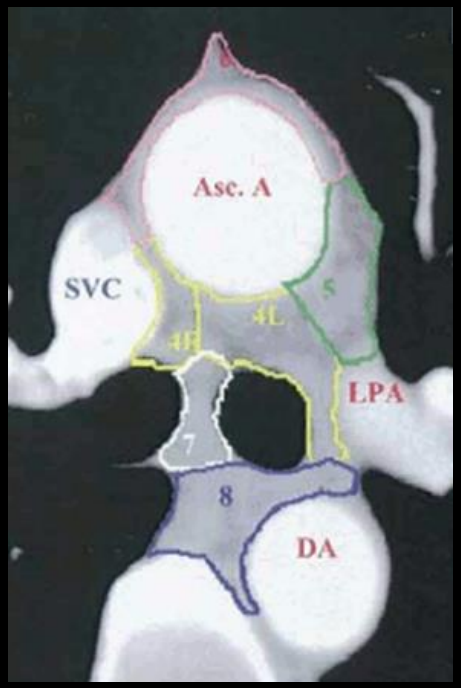


Chapet, IJROBP2005

**Dolna granica = dolna granica gr.7, czyli:**
**- strona L: górny brzeg oskrz. dolnopłatowego L,**
**- strona P: dolny brzeg oskrz. pośredniego .**
**Na tym poziomie kończymy też gr.8. (nie obejmujemy całej - anatomicznie sięga ona do przepony!)**

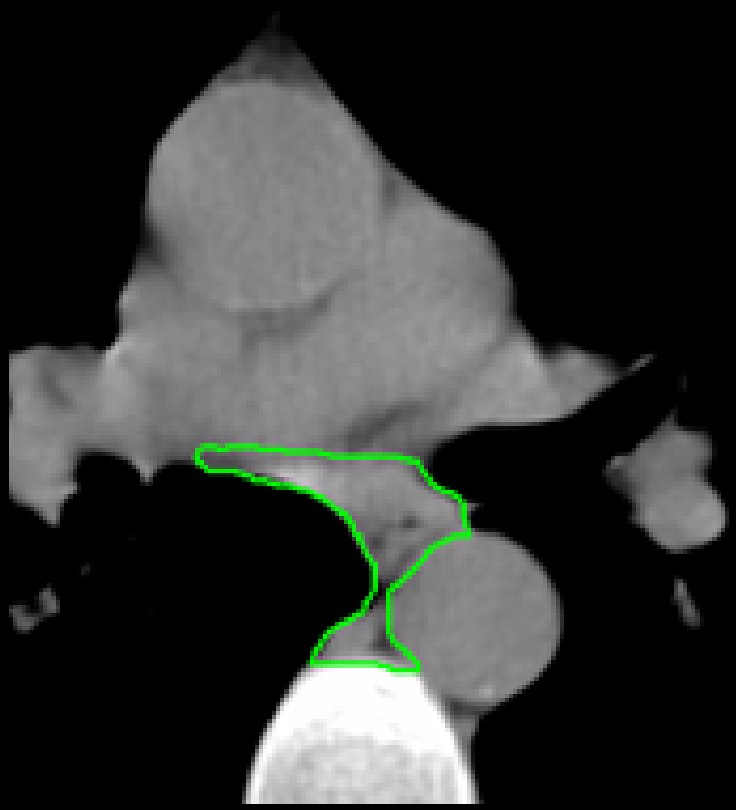

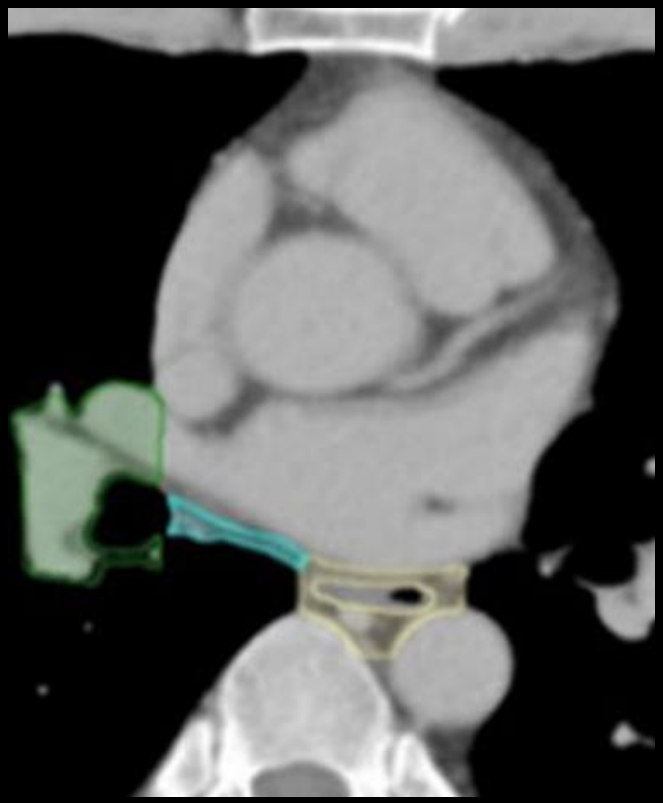

Itazawa 2016

# CTV „węzłowy” – odcinek piersiowy ŚRODKOWY

Podejście indywidualne:

- Stan kliniczny chorego **(!!!)** + sytuacja kliniczna

/Perez, 6th ed.; deVoorde R&O 2014 /

- Stopień zaawansowania: cecha T, N, (G), długość nacieku:
  - śródpiersie środkowe (na odcinku: guz + 4cm góra-dół?)
    - T1-2
    - Dł. ≤ 4cm
    - Dobrze zróżnicowane (G1/2)
  - śródp. środkowe, dolne, ww. chł. nadbrzusza
    - T3-4
    - Dł. > 4cm
    - Źle zróżnicowane (G3) /Cheng, JTO2013 **(1893pts!)**/

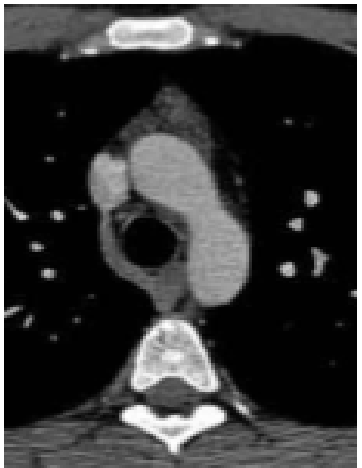

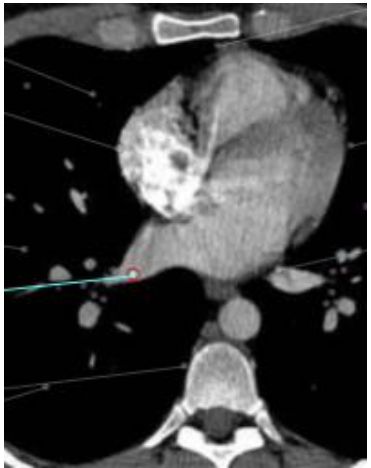

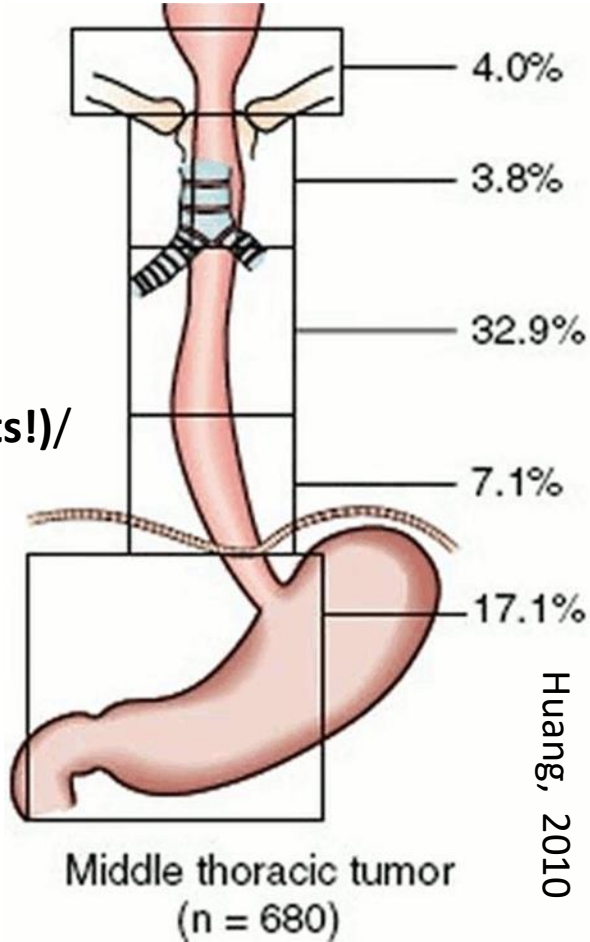


Huang, 2010

# CTV „węzłowy” – odcinek piersiowy DOLNY

Zakres:

- klp: gr. 7, 8, ww. chł. „nadprzeponowe”
  - do cariny? /Huang, R&O 2015/
  - 4 cm powyżej guza? /Wu, IJROBP 2014/
- jama brzuszna (nadbrzusze):
  - Okołowpustowe (1 i 2)
  - Krzywizny mniejszej (3)
  - T. żołądkowej lewej (7)

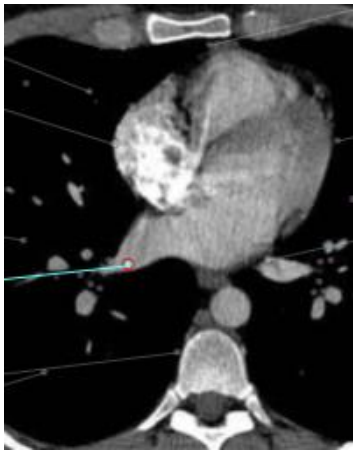

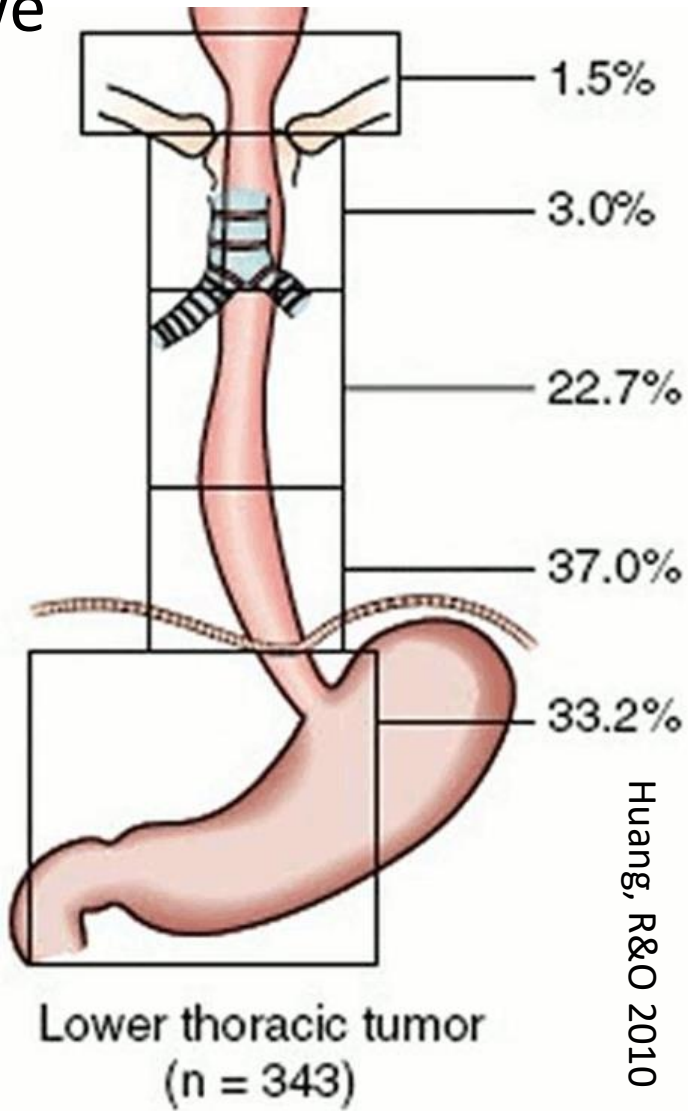


Huang, R&O 2010

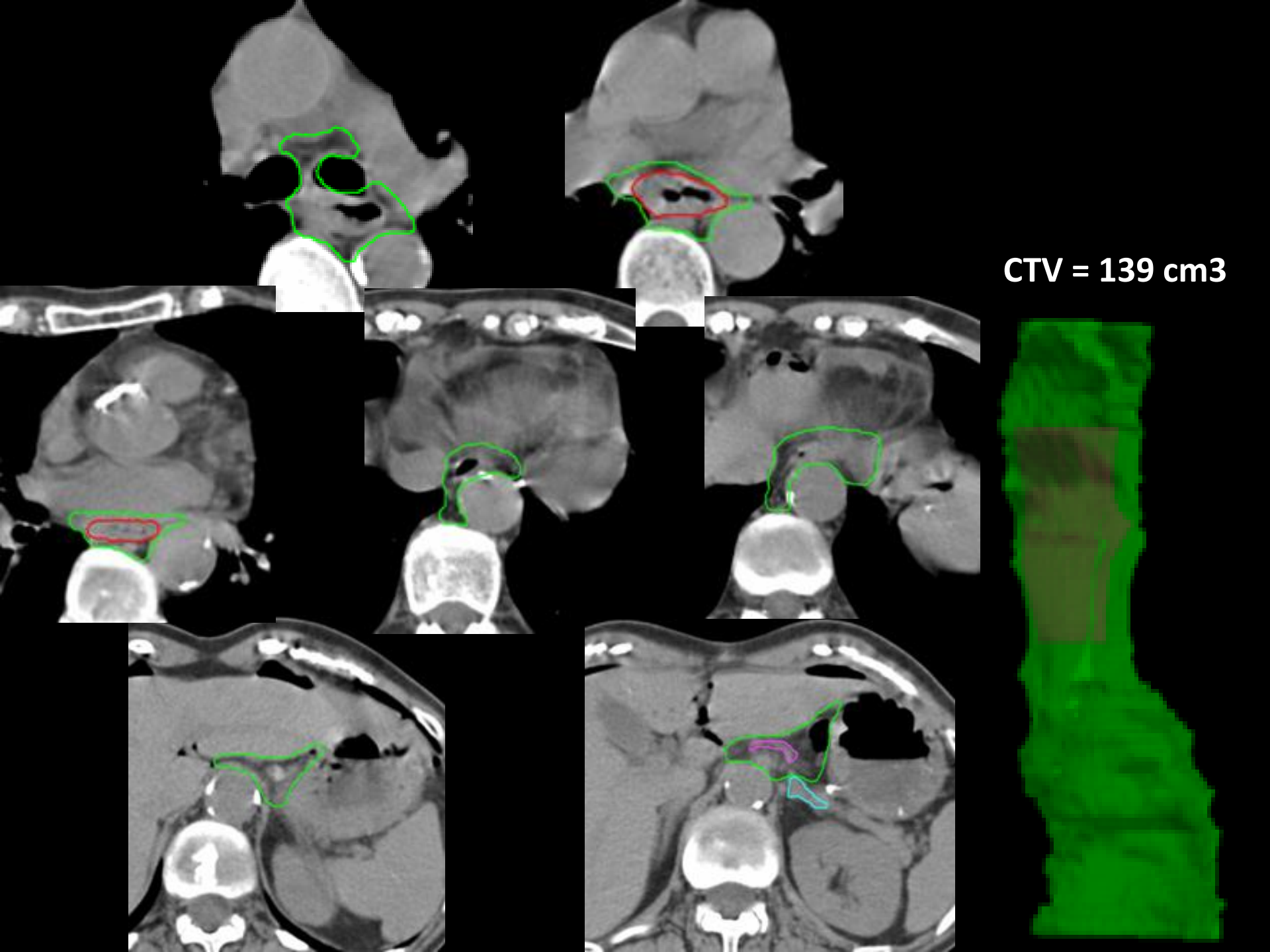
CTV = 139 cm3

## Carina: jeszcze 4RiL, 7, 3P → 8

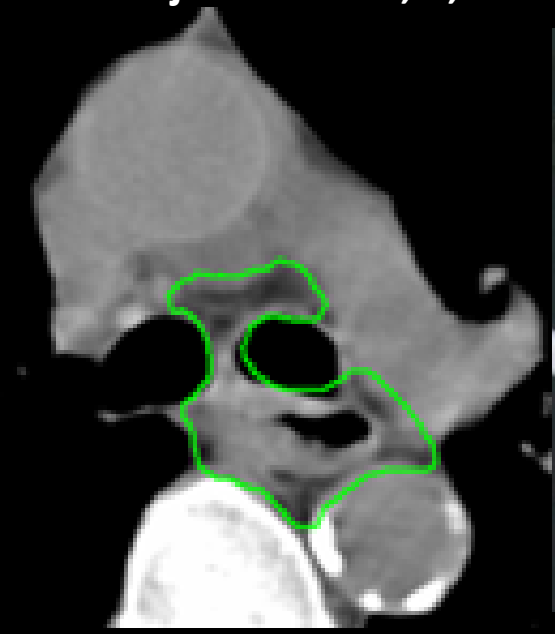

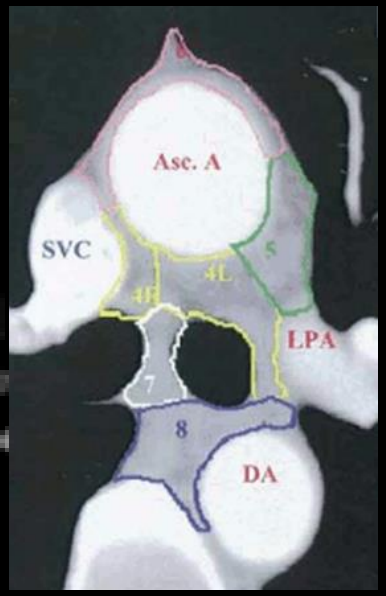


Chapet, IJROBP2005

## Gr. 7 (ost. slajd), 8

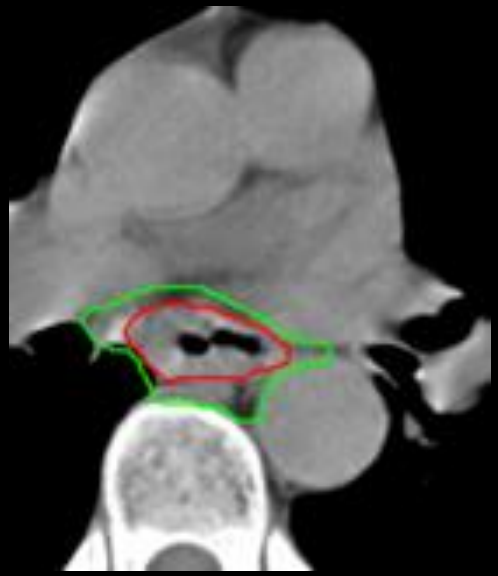

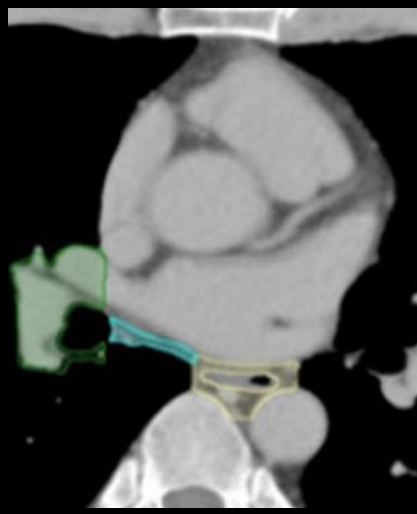

Itazawa 2016

## Dolne śródpiersie: gr.8

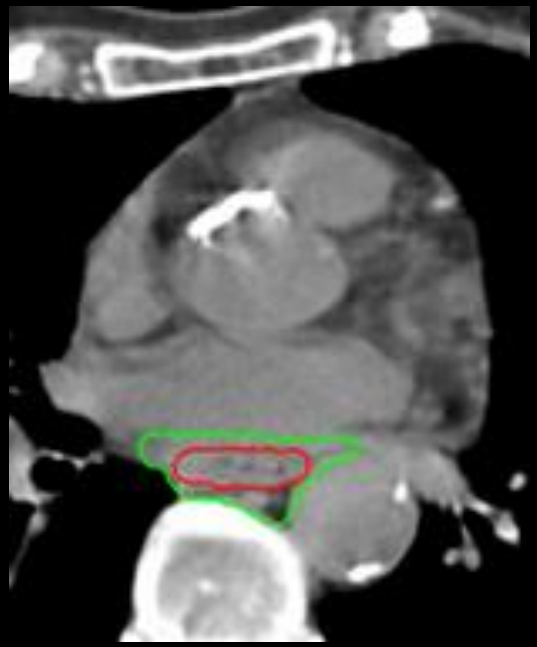

Itazawa 2016

## Ww.chł. „nadprzeponowe”

Huang, R&O 2015

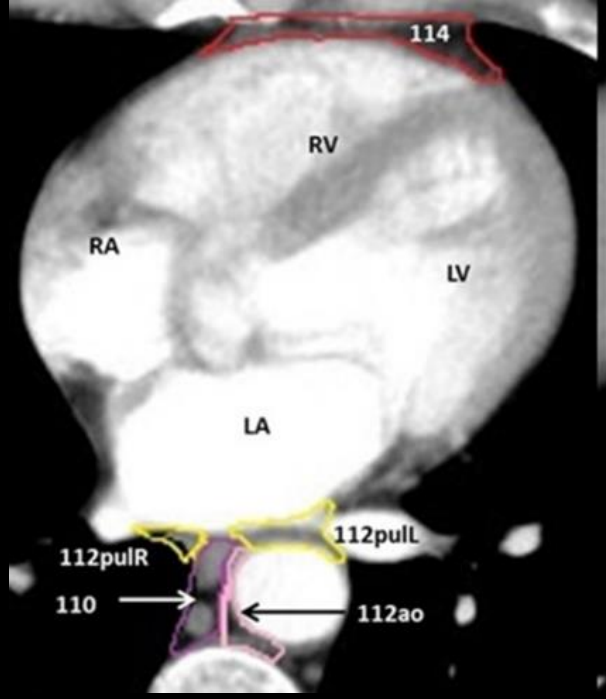


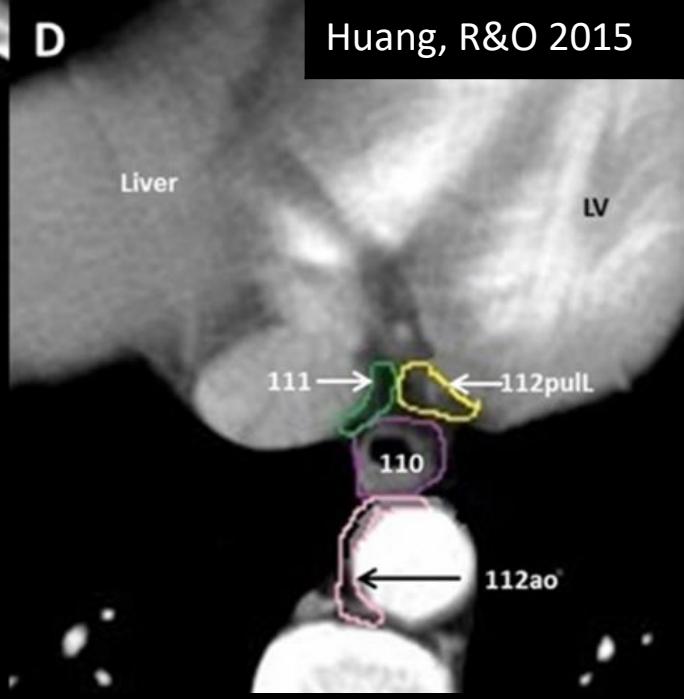


## Ww. chł. okołowpustowe prawe i lewe – gr. 1 i 2

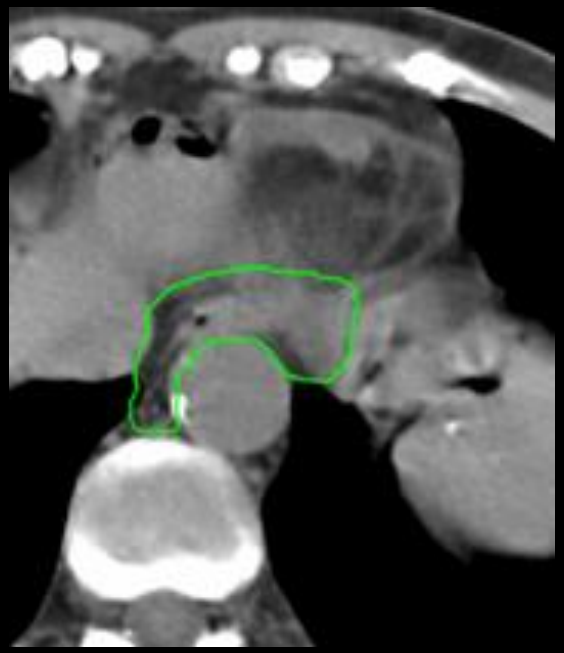

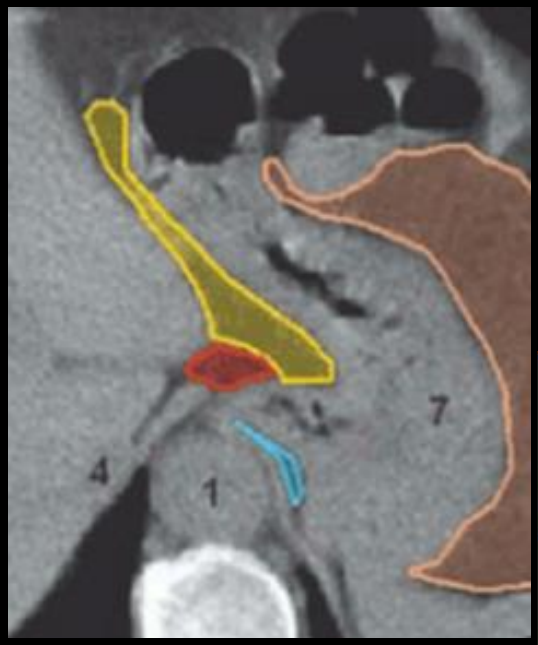




**Ww.chł. krzywizny mniejszej – gr.3**

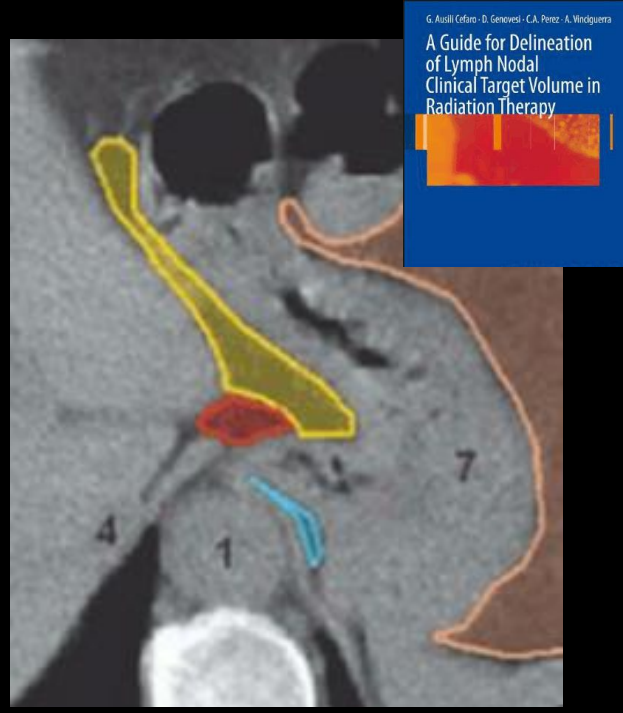


**Ww. chł. krzywizny mniejszej (gr.3) i t. żołądkowej lewej (gr.7)**

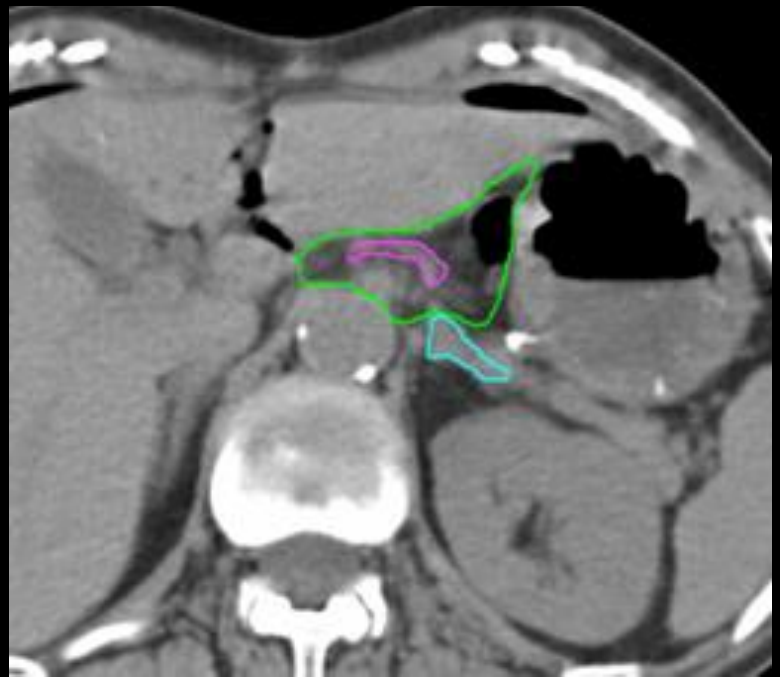

**WIĘZADŁO ŻOŁĄDKOWO – WĄTROBOWE**

t. żołądkowa lewa LGA

nadnercze

# RAK EGJ

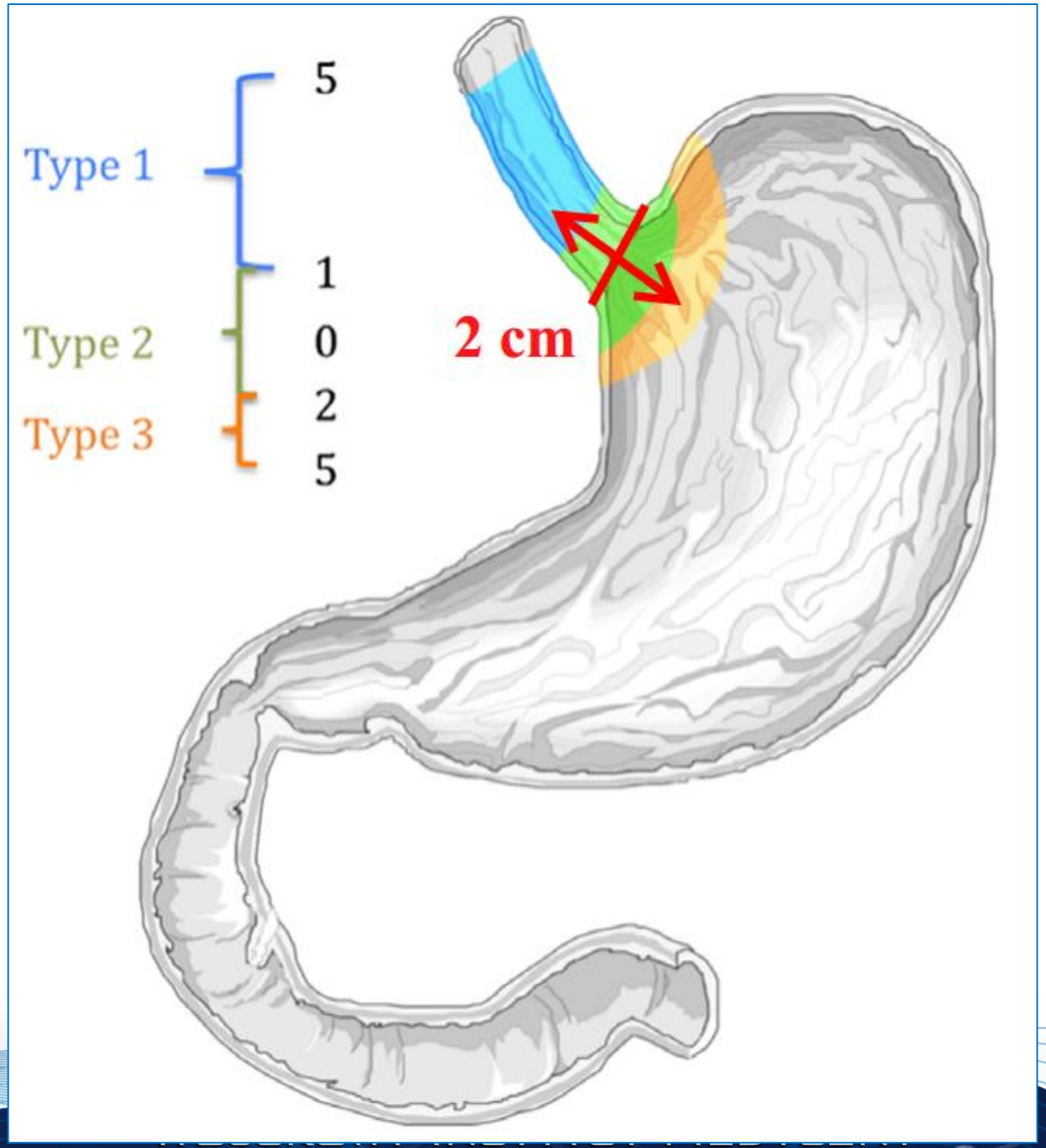

# CTV „węzłowy” – EGJ

- Śródpiersie dolne
  - 3-4cm powyżej GTV? /Wu, IJROBP 2014/
  - do cariny włącznie? ocena **DVH – VS5 dla płuc**!

/Meier, IJROBP 2008; Wang, IJROBP 2006/

- Węzły chłonne okołoaortalne od poziomu EGJ

/Wu, IJROBP 2014/

- Jama brzuszna
  - Okołowpustowe (1 i 2)
  - Krzywizny mniejszej (3)
  - T. żołądkowej lewej (7)
  - Pnia trzewnego (9) /Wu, IJROBP 2014; Machiels JMIRO 2016; Garcia 2016/

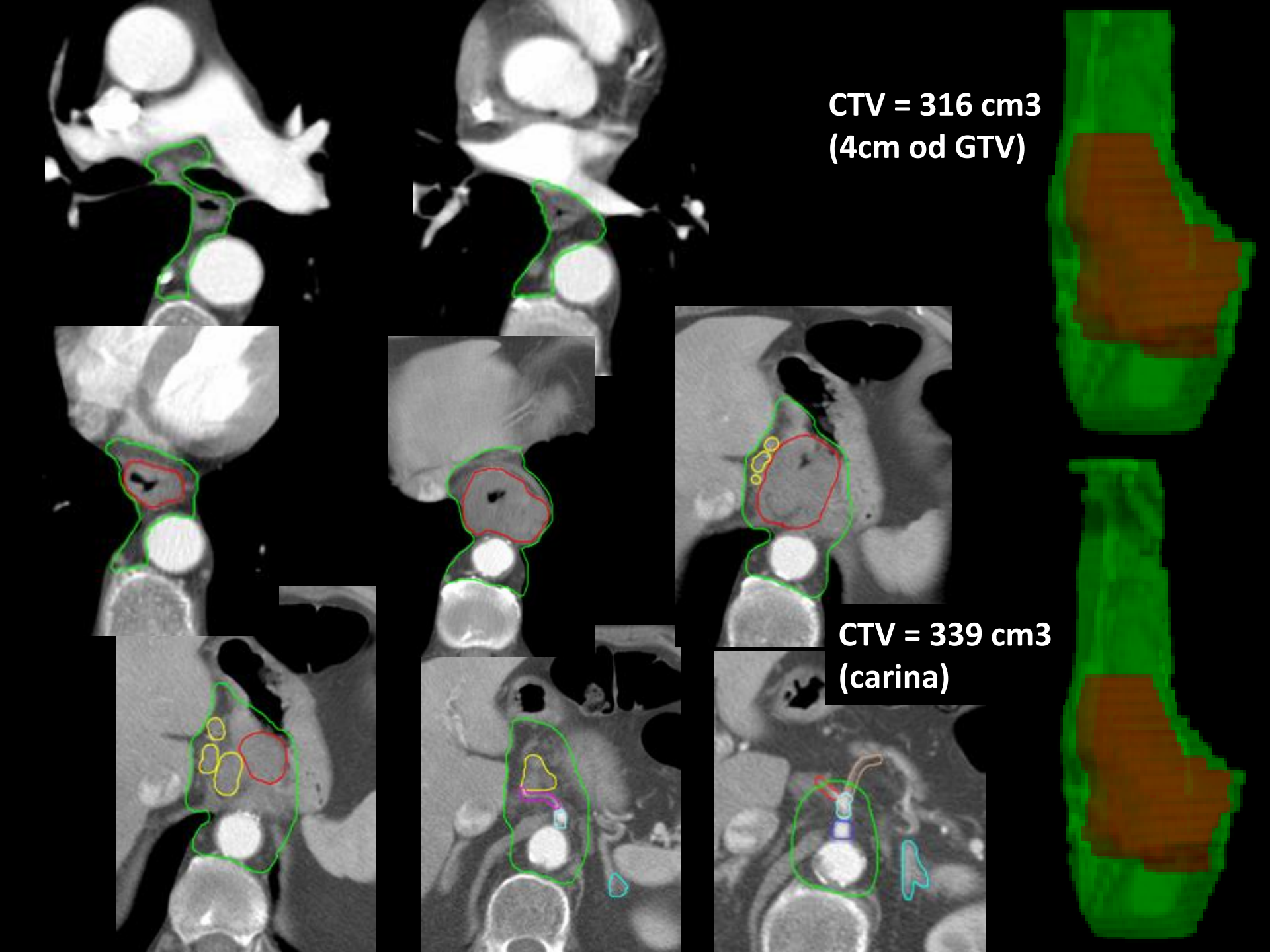
CTV = 316 cm3
(4cm od GTV)
CTV = 339 cm3
(carina)

Górna granica CTV: carina; gr. 7 i 8

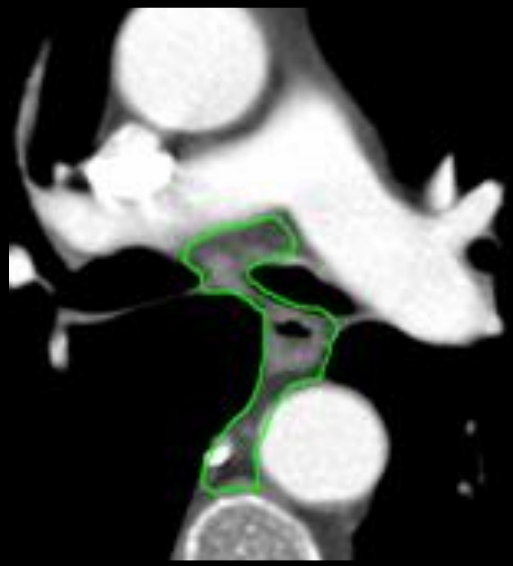

Górna granica CTV: 4cm nad GTV, gr. 8

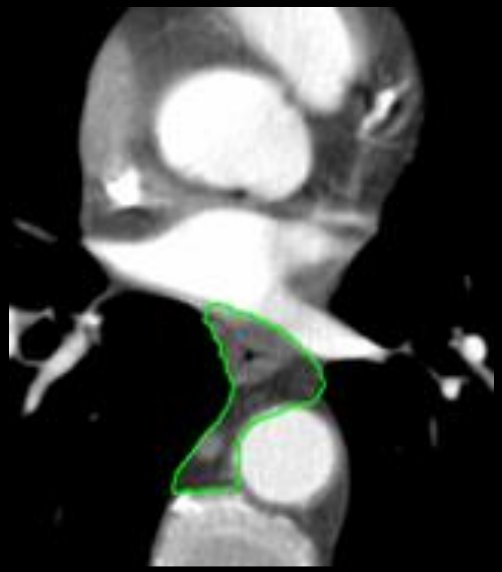

Górny biegun GTV, gr.8

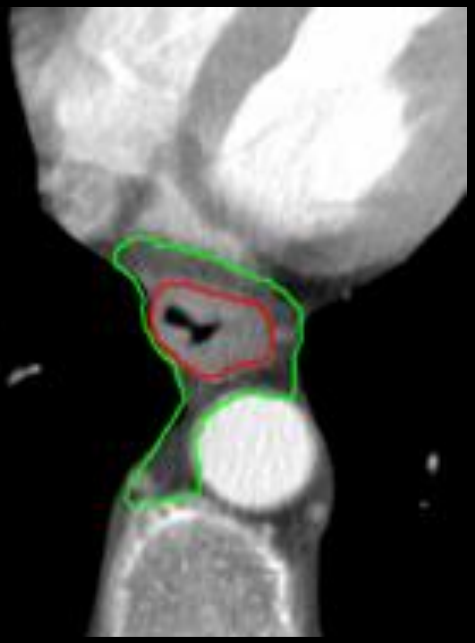

Rozwór przełykowy, główna masa guza. Obejmujemy Ao od tego poziomu - gr. 16

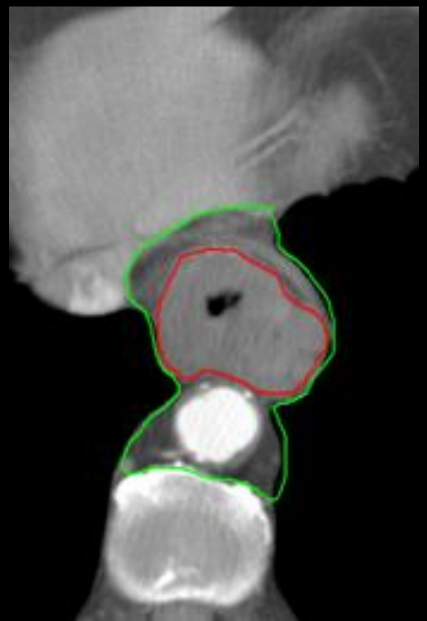

VS

Ww.chł. okołowpustowe
Bez okołoaortalnych
(CTV rak przełyku)

Wu, IJROBP 2014

Ww.chł. krzywizny mniejszej – gr.3, ww. chł. +, więzadlo wątrobowo-żołądkowe!

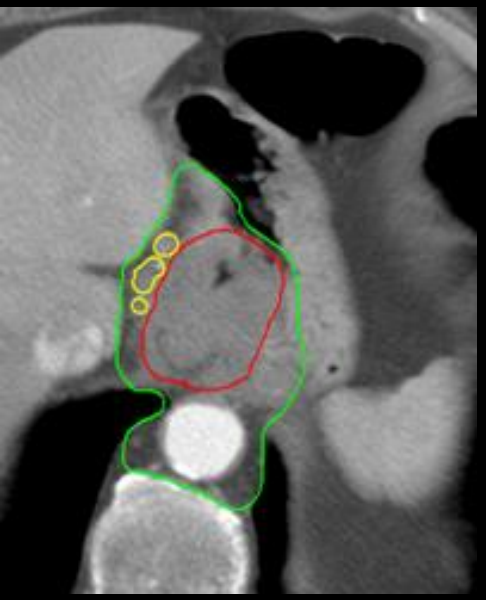

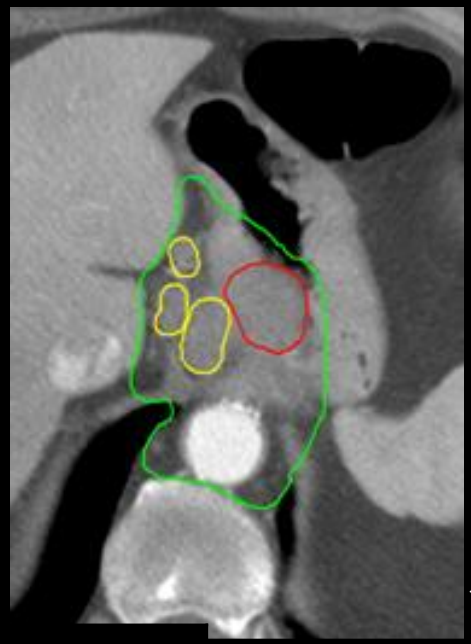

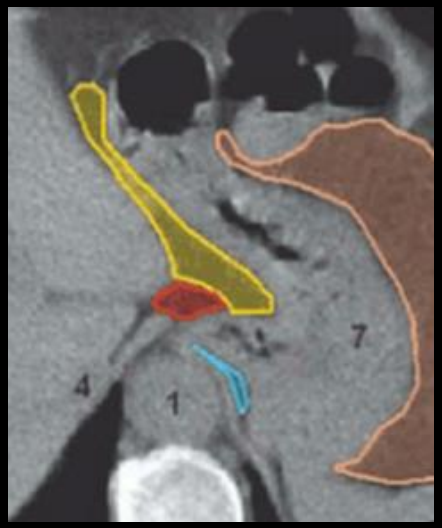


← Dolny biegun GTV

CT SMA
LGA CHA SplA
SRG N+

Ww. chł. krzywizny mniejszej (gr.3) i t. żołądkowej lewej (gr.7)

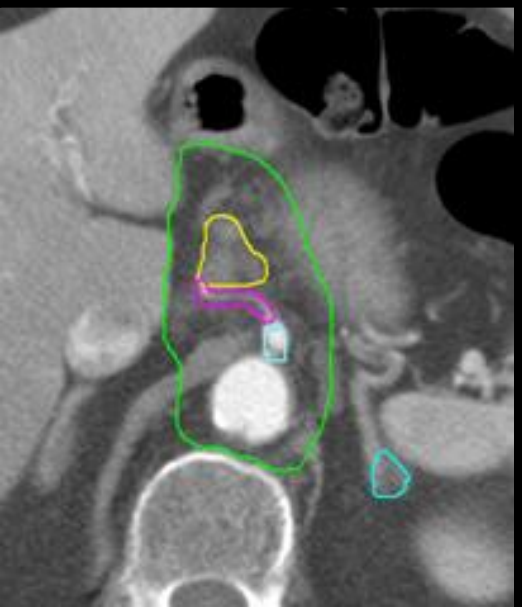

Ww. chł. pnia trzewnego (gr.9)

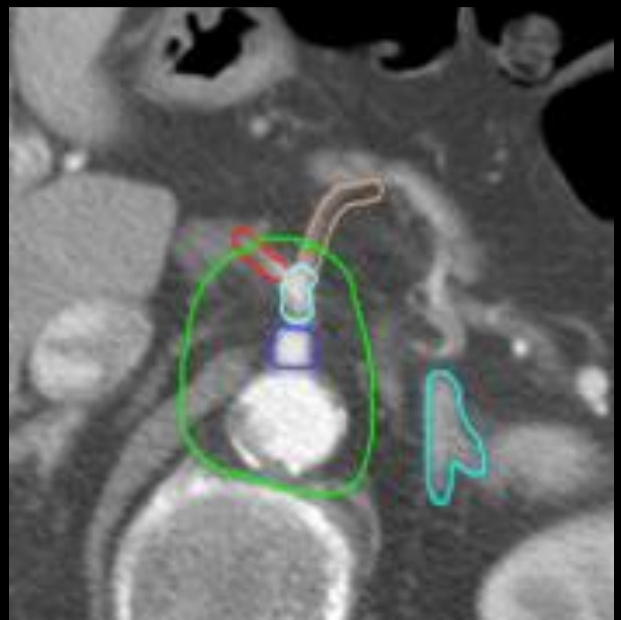

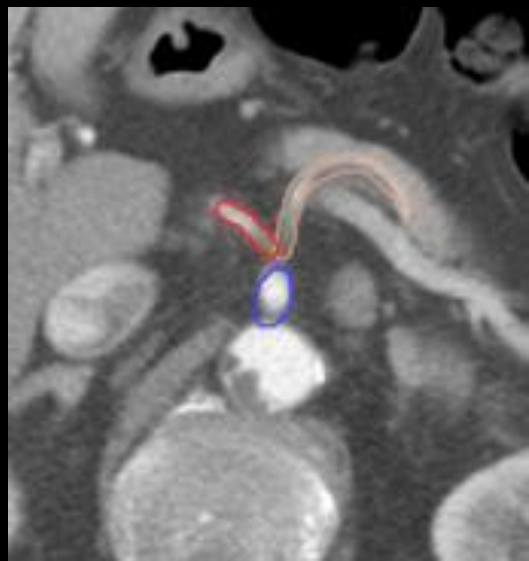

# Węzły chłonne okołoaortalne a CTV w raku EGJ

CTV GTV CT SMA SplA LGA

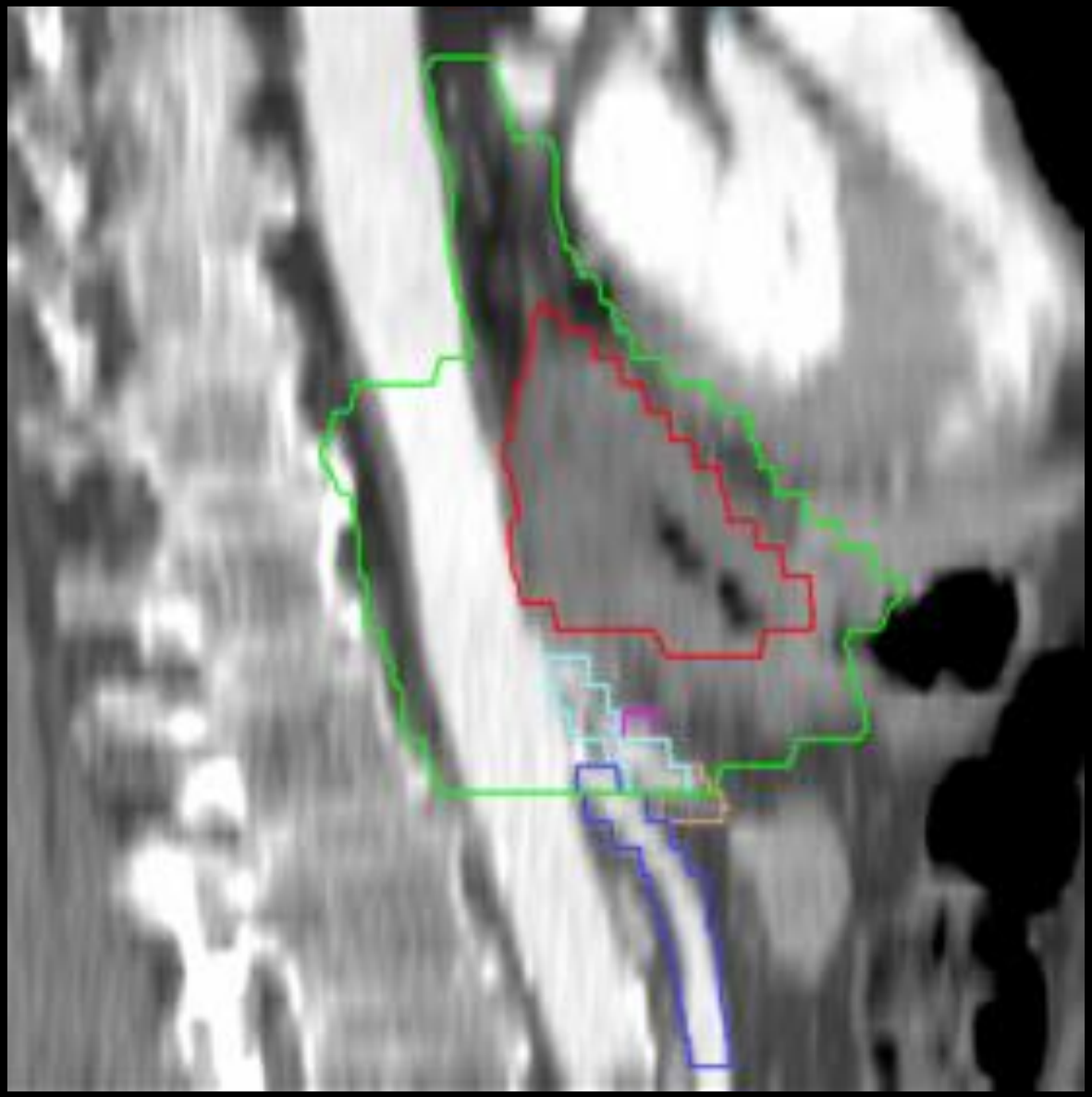

# RAK ŻOŁĄDKA


ajcc
Cancer Staging Atlas
A Companion to the Seventh Editions of the AJCC Cancer Staging Manual and Handbook
SECOND EDITION
Springer

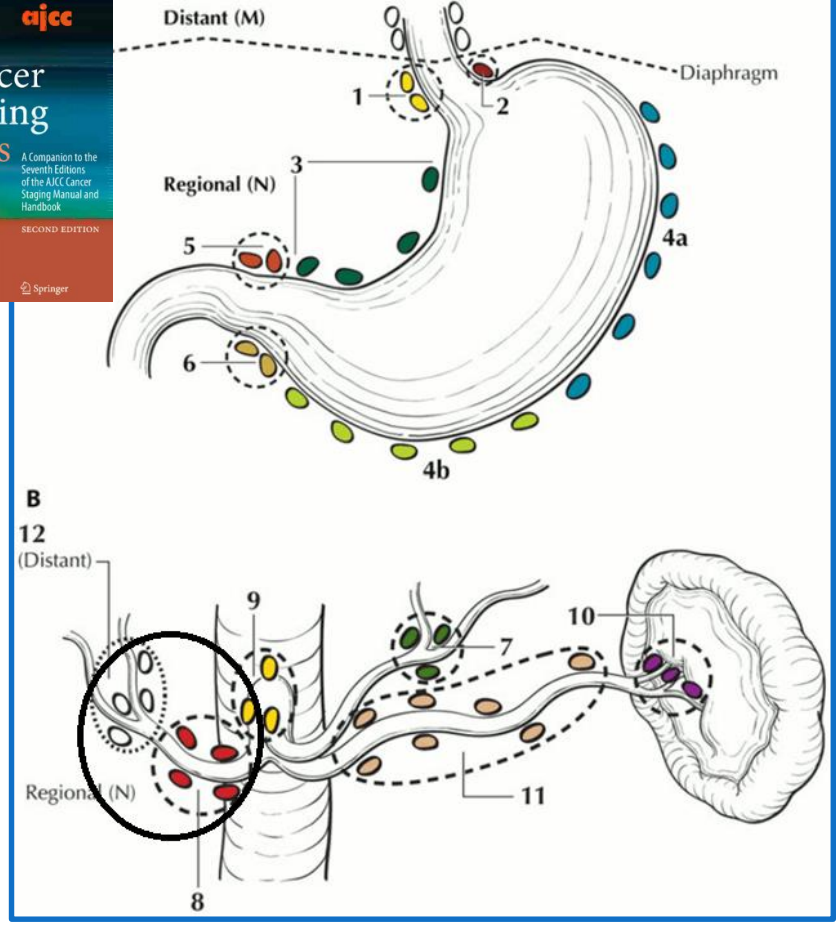
Distant (M)
Diaphragm
1
2
3
Regional (N)
5
4a
6
4b
B
12
(Distant)
9
10
7
Regional (N)
11
8

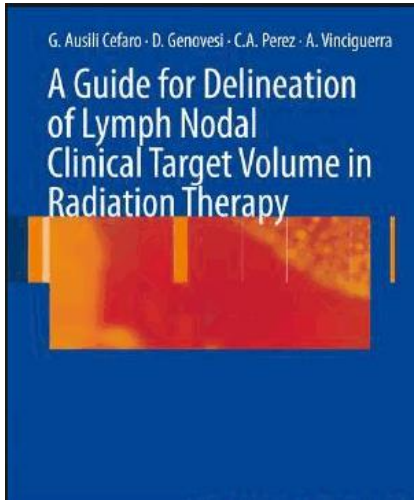
G. Ausili Cefaro · D. Genovesi · C.A. Perez · A. Vinciguerra
A Guide for Delineation of Lymph Nodal Clinical Target Volume in Radiation Therapy

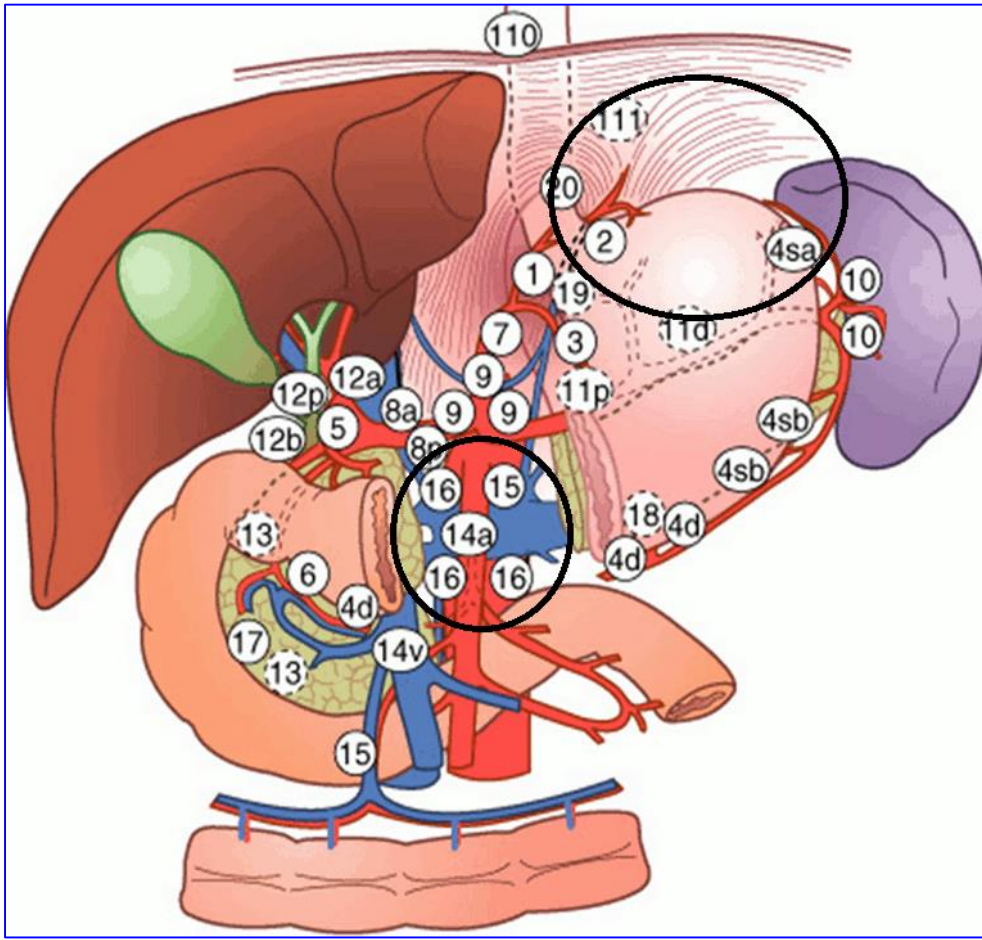
110
111
20
2
4sa
1
19
10
7
3
11d
10
9
12a
12p
8a
9
9
11p
5
12b
8p
4sb
4sb
16
15
18
4d
13
14a
4d
6
16
16
4d
17
14v
13
15

# CTV – loża pooperacyjna: ocena stosunku nacieku żołądka do narządów sąsiednich:

# TK PRZEDOPERACYJNA!

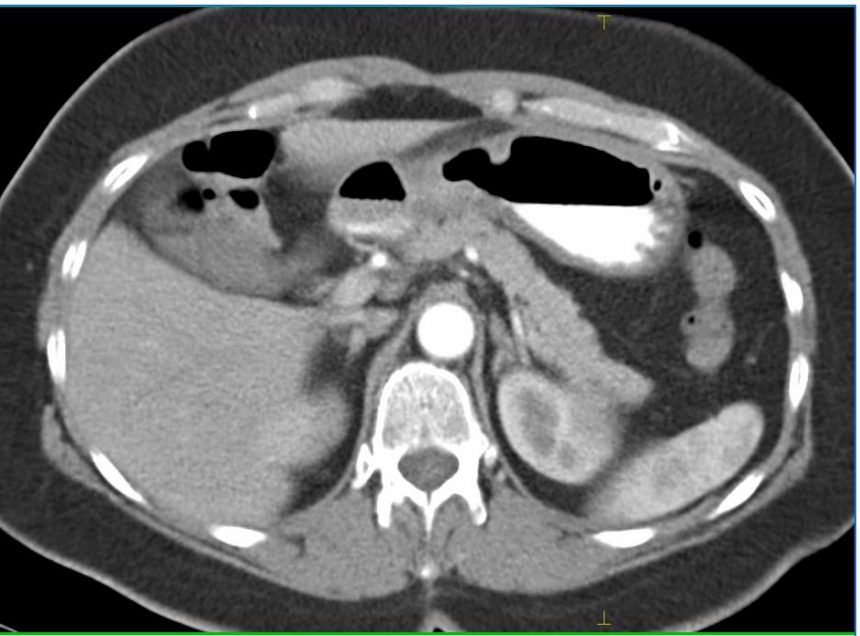

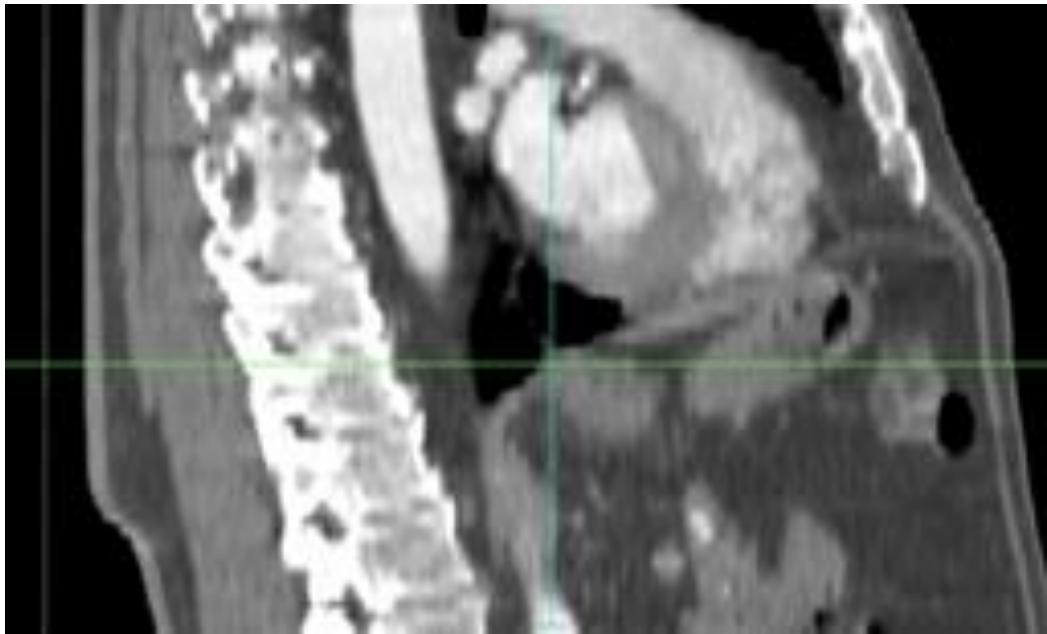

# CTV – loża pooperacyjna: stosunek do przepony

**TK PRZEDOPERACYJNA!**

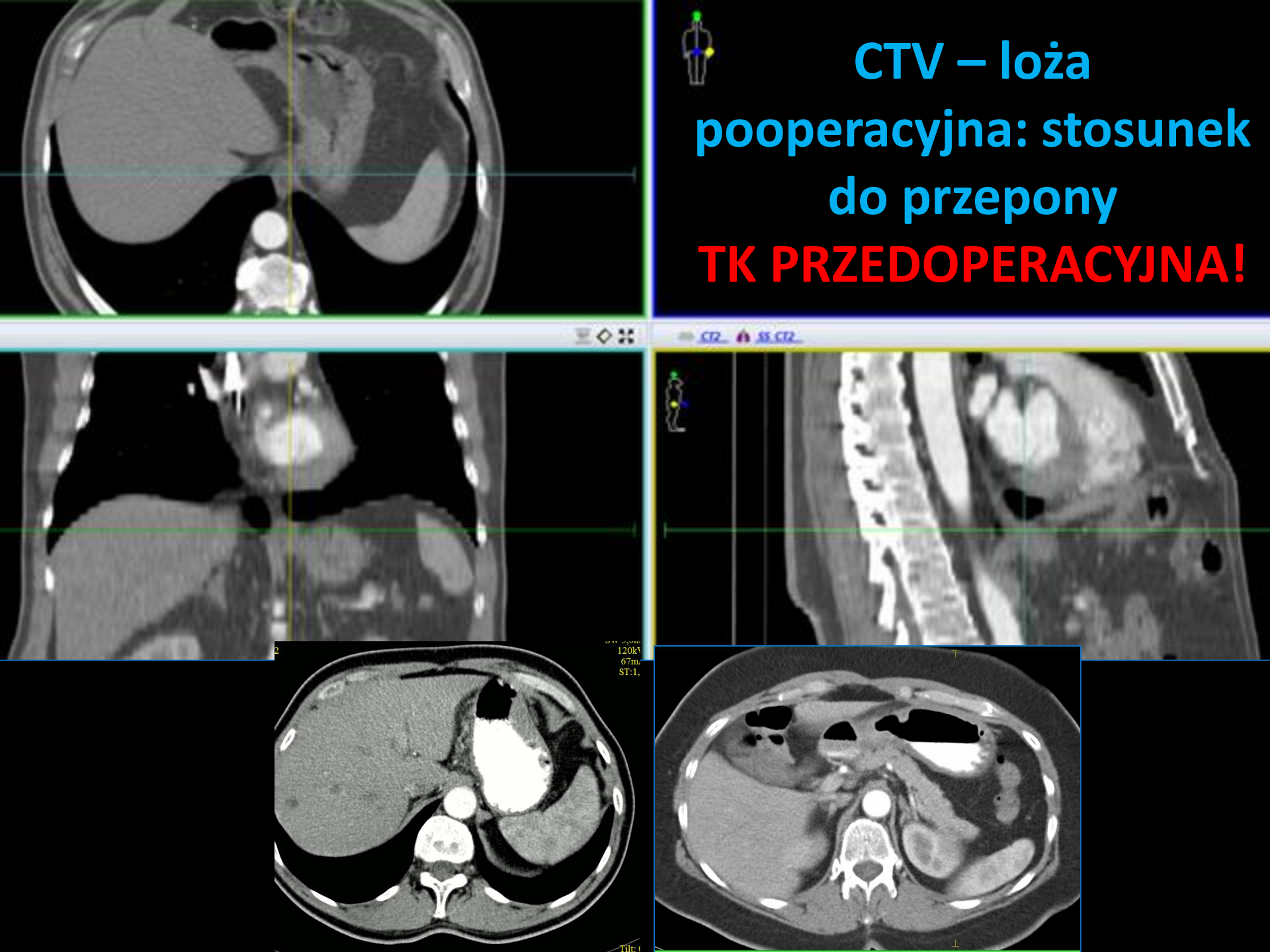

# WNĘKA WĄTROBY: gr. 8 (CHA) i 12 (PHA)

www.impactjournals.com/oncotarget/ Oncotarget, 2017, Vol. 8, (No. 25), pp: 41465-41473

Research Paper

## Consistency mapping of 16 lymph node stations in gastric cancer by CT-based vessel-guided delineation of 255 patients

Shuhang Xu[1,*], Lingling Feng[2,3,*], Yongming Chen[2,4,*], Ying Sun[2,3], Yao Lu[5], Shaomin Huang[2,3], Yang Fu[6], Rongqin Zheng[1], Yujing Zhang[2,3] and Rong Zhang[2,7]

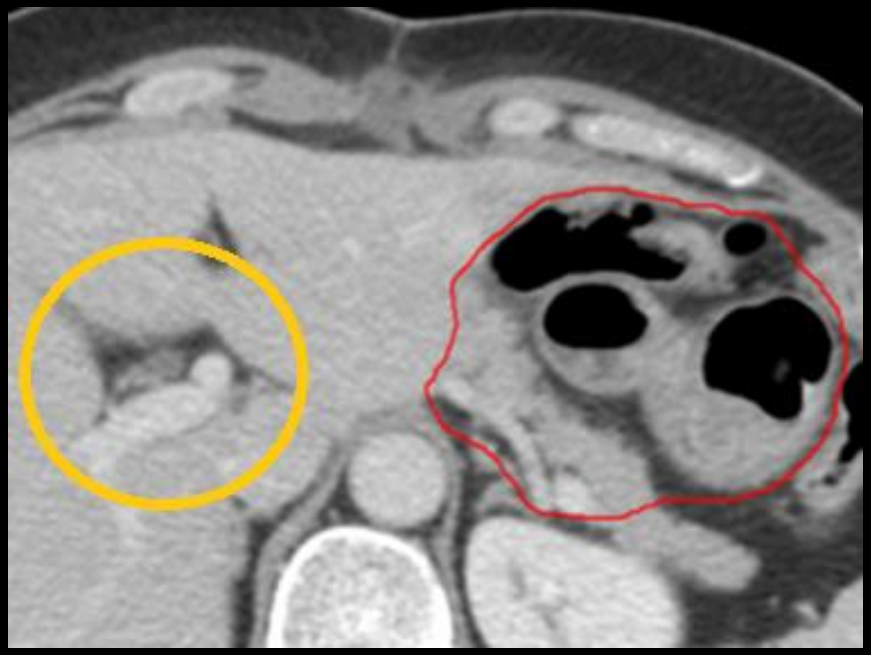

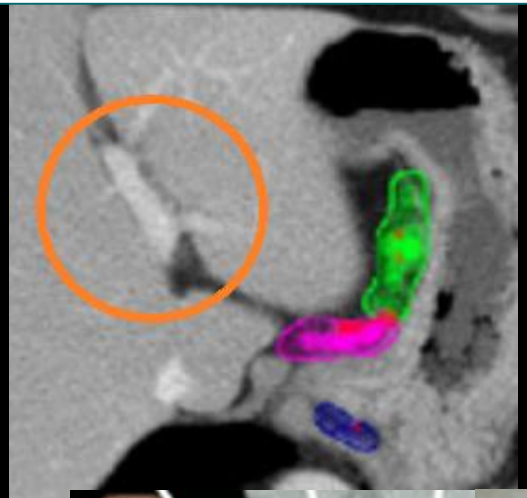

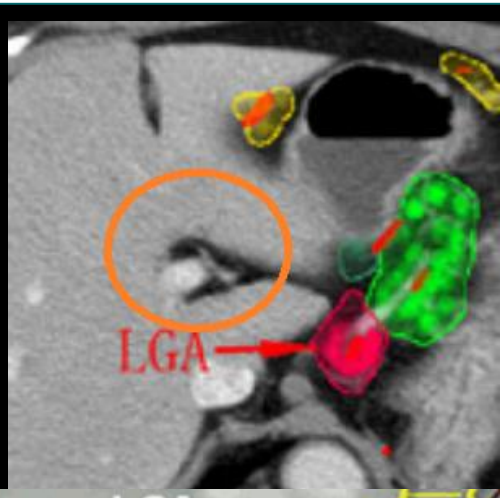

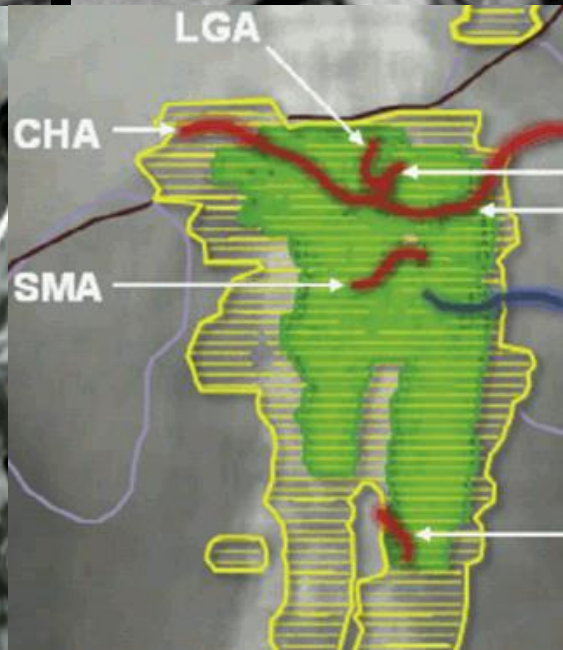


ELSEVIER

Contents lists available at SciVerse ScienceDirect

Radiotherapy and Oncology

journal homepage: www.thegreenjournal.com

Original article

## Defining the target volume for post-operative radiotherapy after D2 dissection in gastric cancer by CT-based vessel-guided delineation

Hong In Yoon [a,e,1], Jee Suk Chang [a,1], Joon Seok Lim [b,*], Sung Hoon Noh [c], Woo Jin Hyung [c], Ji Yeong An [c], Yong Chan Lee [d], Sun Young Rha [d], Kyung Hwan Kim [a], Woong Sub Koom [a,*]

# WNĘKA WĄTROBY: gr. 8 (CHA) i 12 (PHA)

## Granica str. prawa = +/- prawy brzeg ż. gł. dolnej?

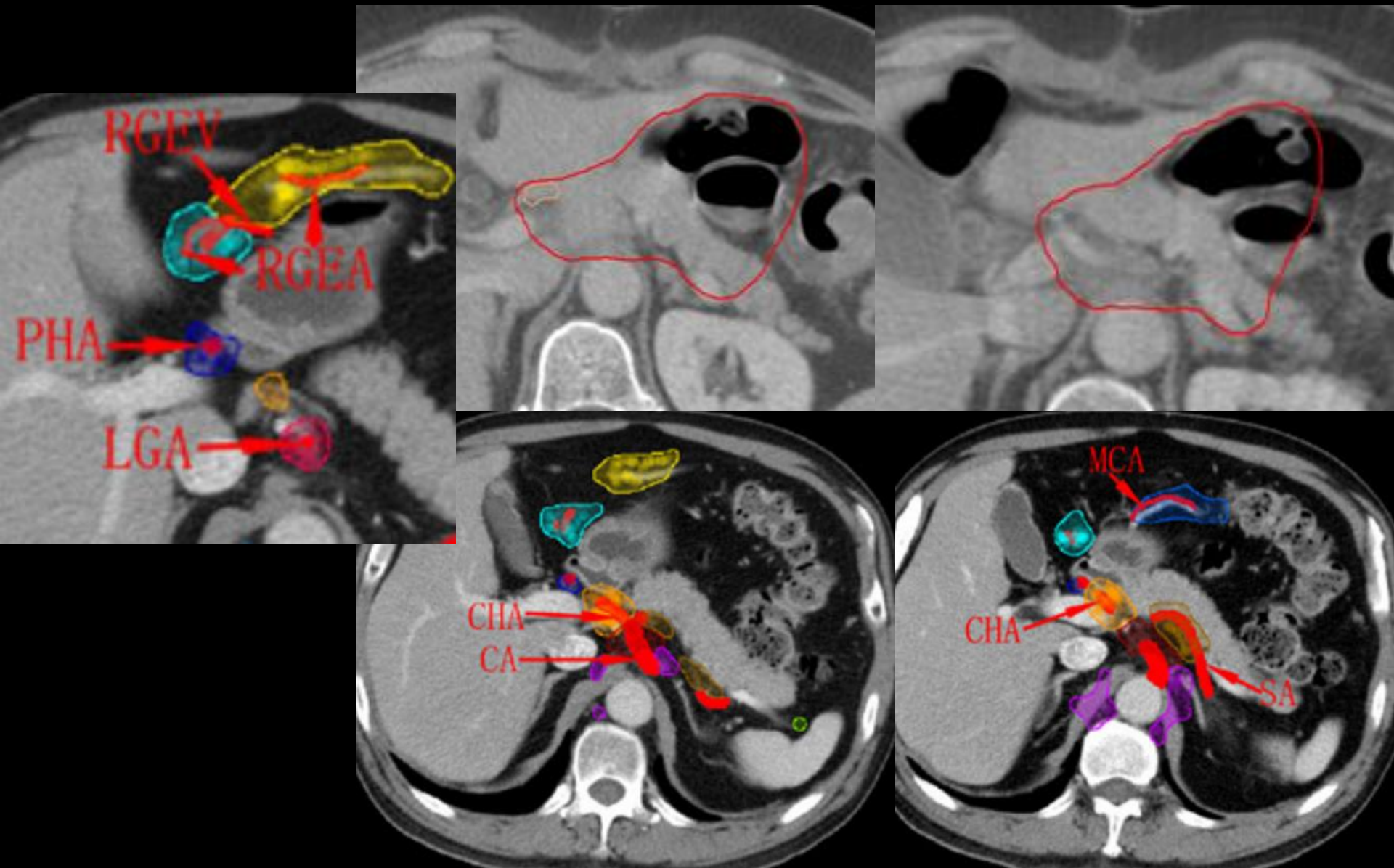

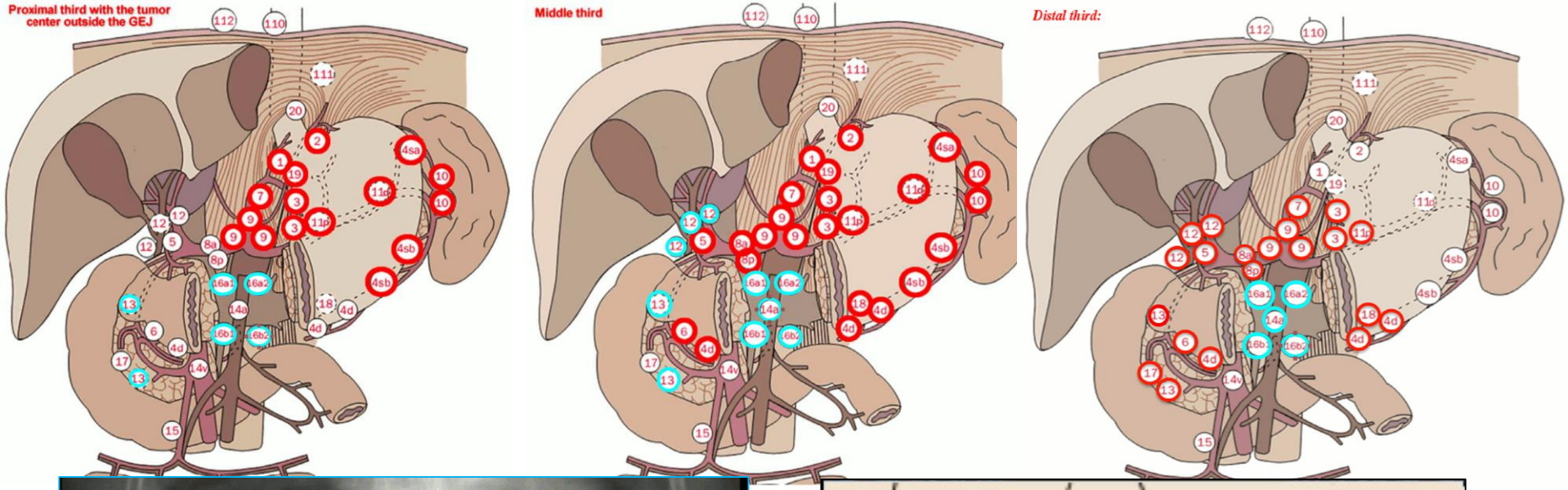


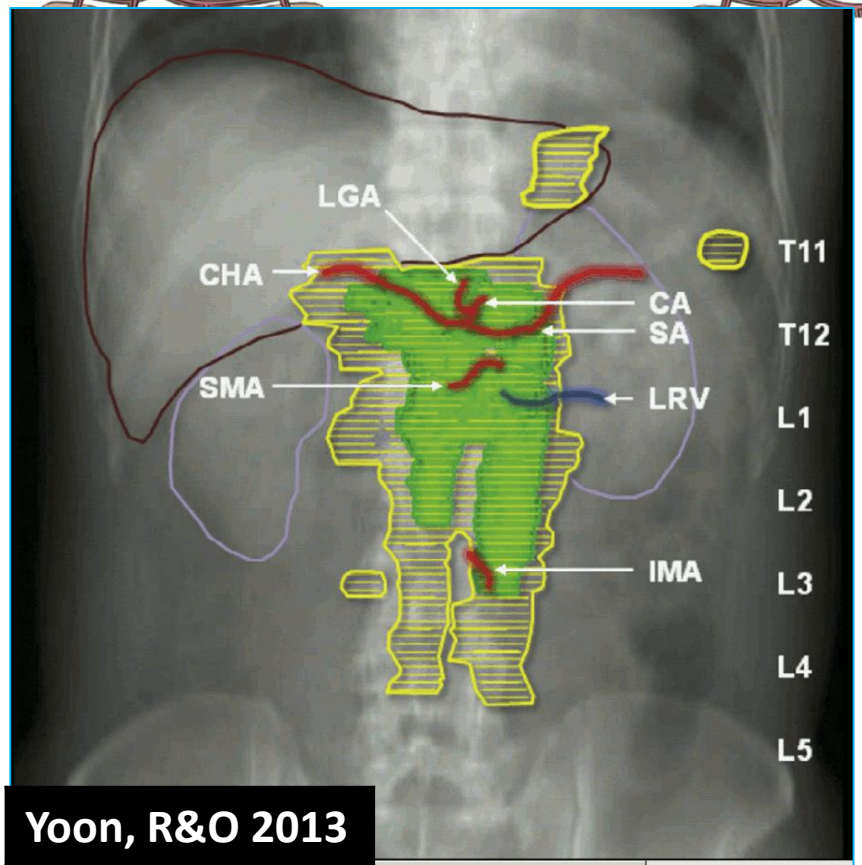


Yoon, R&O 2013

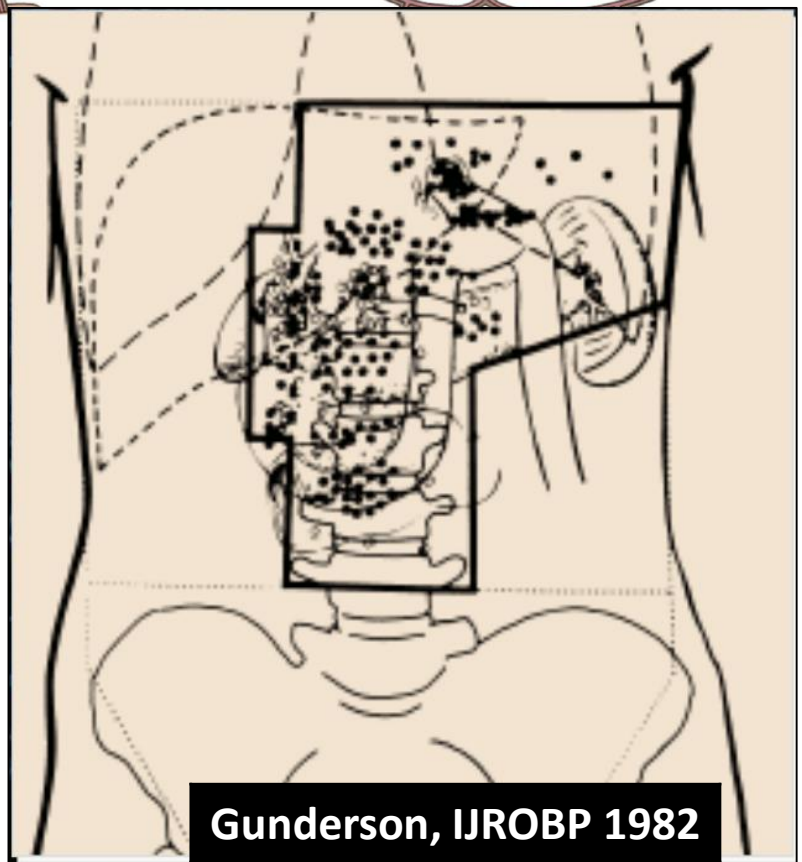

Gunderson, IJROBP 1982

# Węzły chłonne okołoaortalne

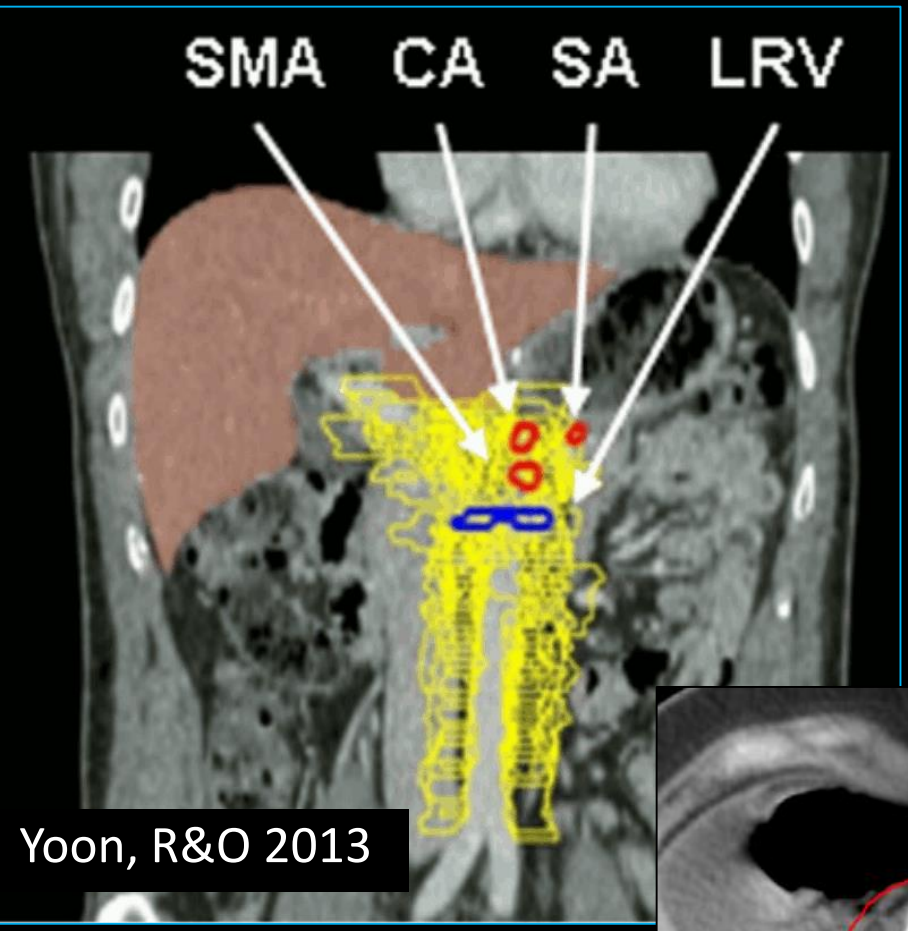


Yoon, R&O 2013

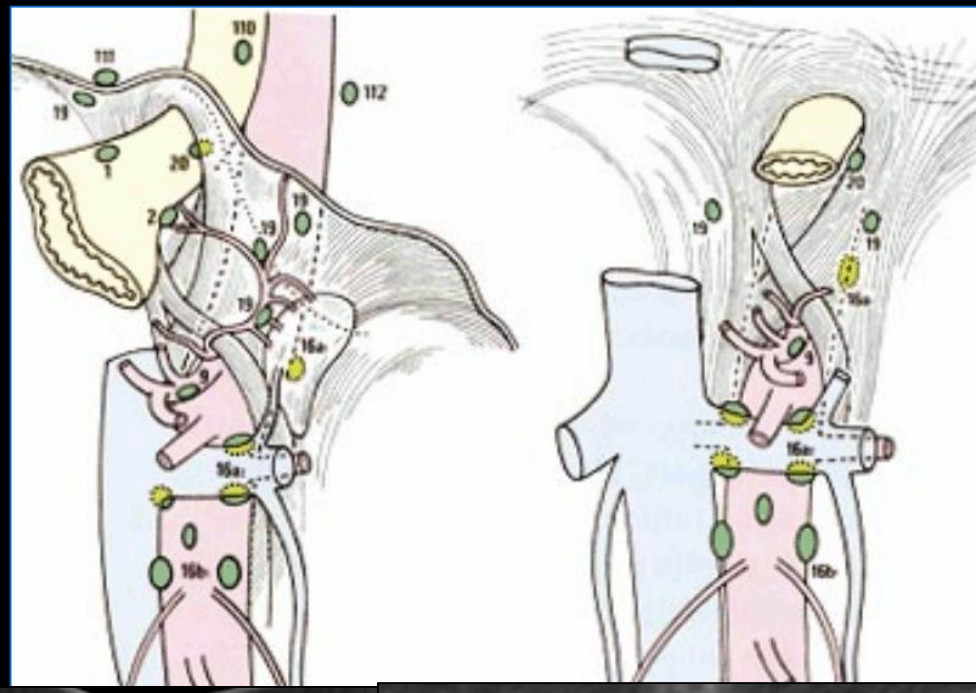

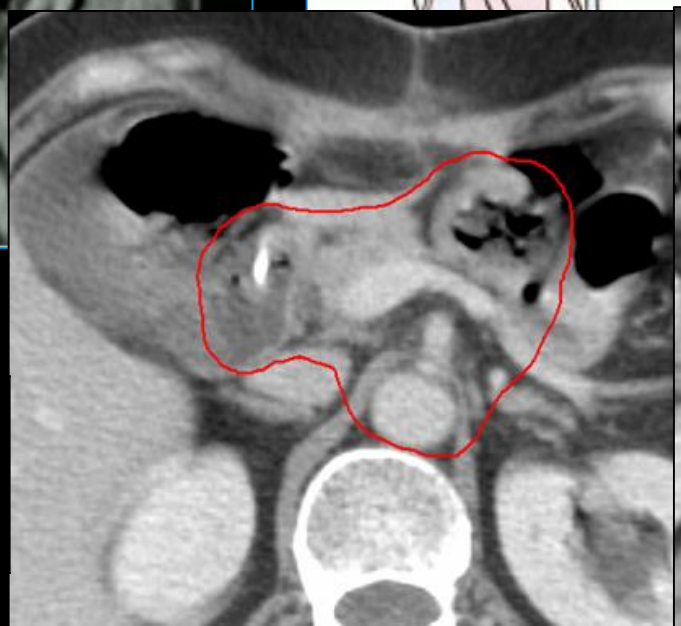

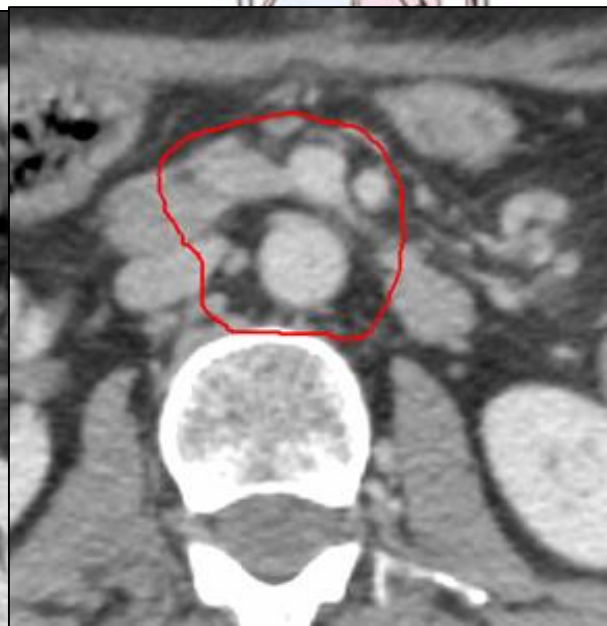

**Pierwszy slajd:**

**Poziom pnia trzewnego**

Yoon R&O 2013

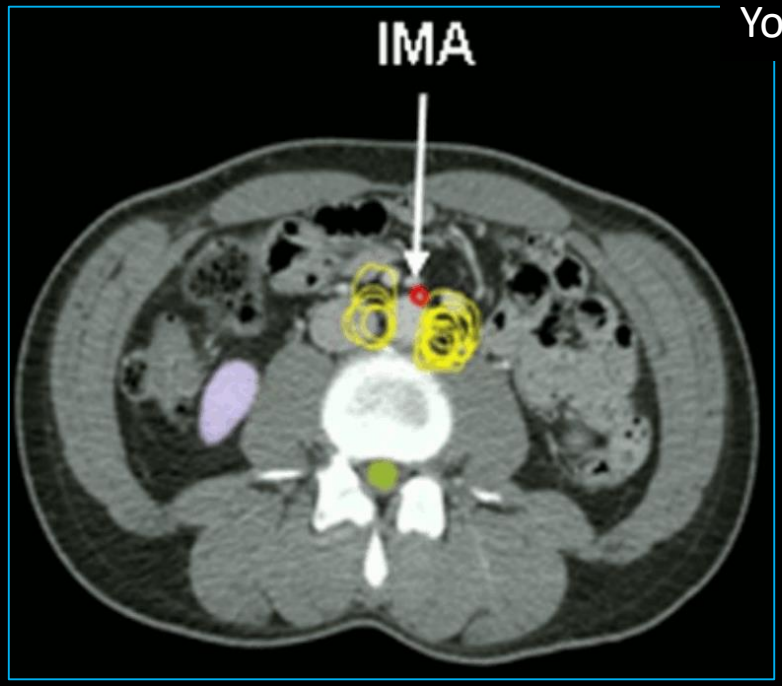


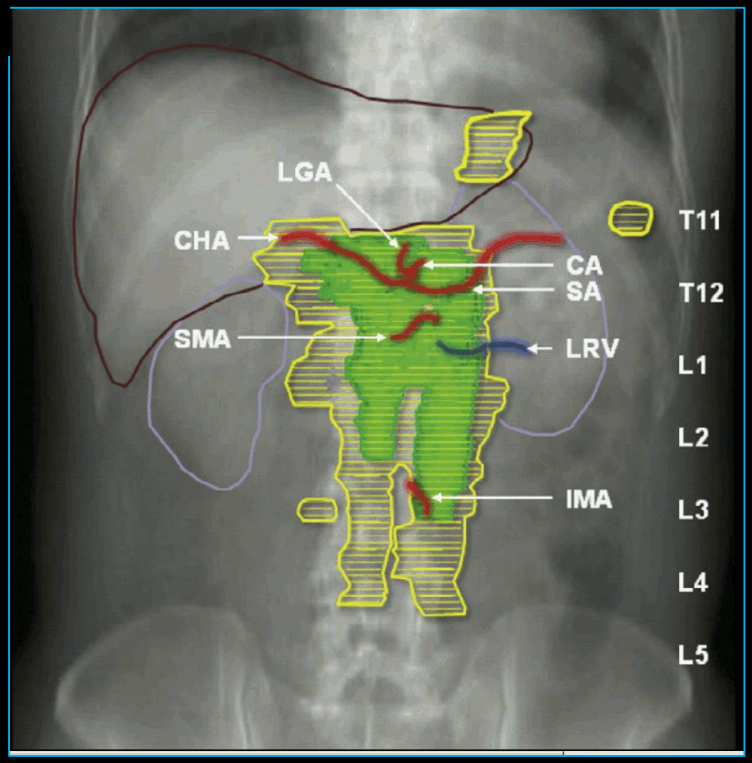

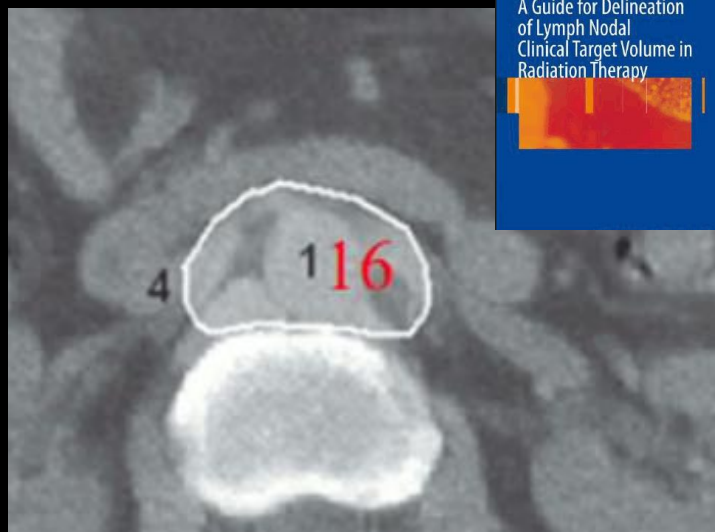





**Ostatni slajd:**

**Odejście IMA**

# Węzły chłonne okołoaortalne :

## CTV w raku żołądka

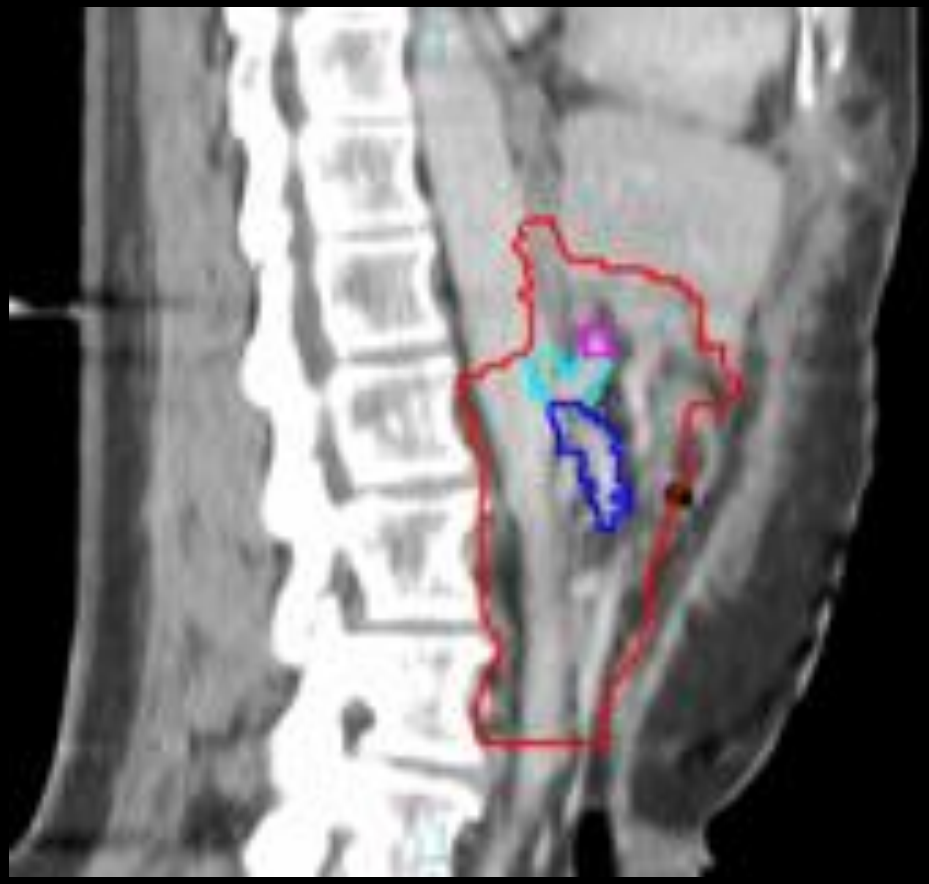

## CTV w raku EGJ

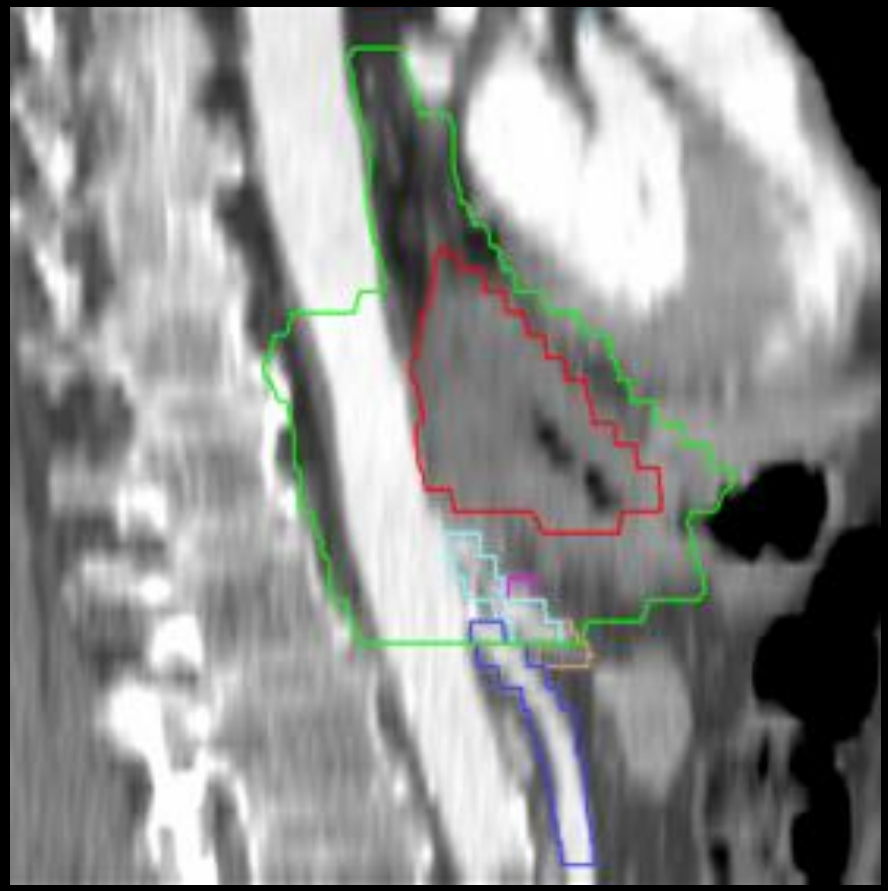

# RAK TRZUSTKI

## CTV „WĘZŁOWY” W RADIOTERAPII POOPERACYJNEJ

# Stepwise Approach to Contouring

- Delineate ROI's
  - Portal Vein (PV)
  - Pancreaticojenunostomy (PJ)
  - Celiac Artery (CA)
  - Superior Mesenteric Artery (SMA)
  - Aorta
  - Tumor Bed
- Expansion 1
  - 1.0 cm expansion on PV, PJ, CA, and SMA
- Expansion 2
  - 2.5 to 3.0 cm to the right,1.0 cm to the left, 2.0 to 2.5 cm anteriorly, 0.2 cm posteriorly on Aorta
- CTV
  - Boolean addition (merging) of Expansion 1 and 2
  - Confirm that CTV encompasses tumor bed and contoured clips
- PTV
  - 0.5 cm expansion on CTV

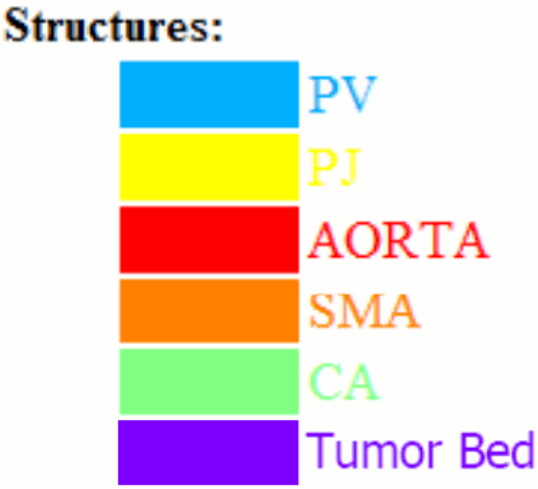


RTOG
RADIATION THERAPY ONCOLOGY GROUP

RTOG
RADIATION THERAPY ONCOLOGY GROUP

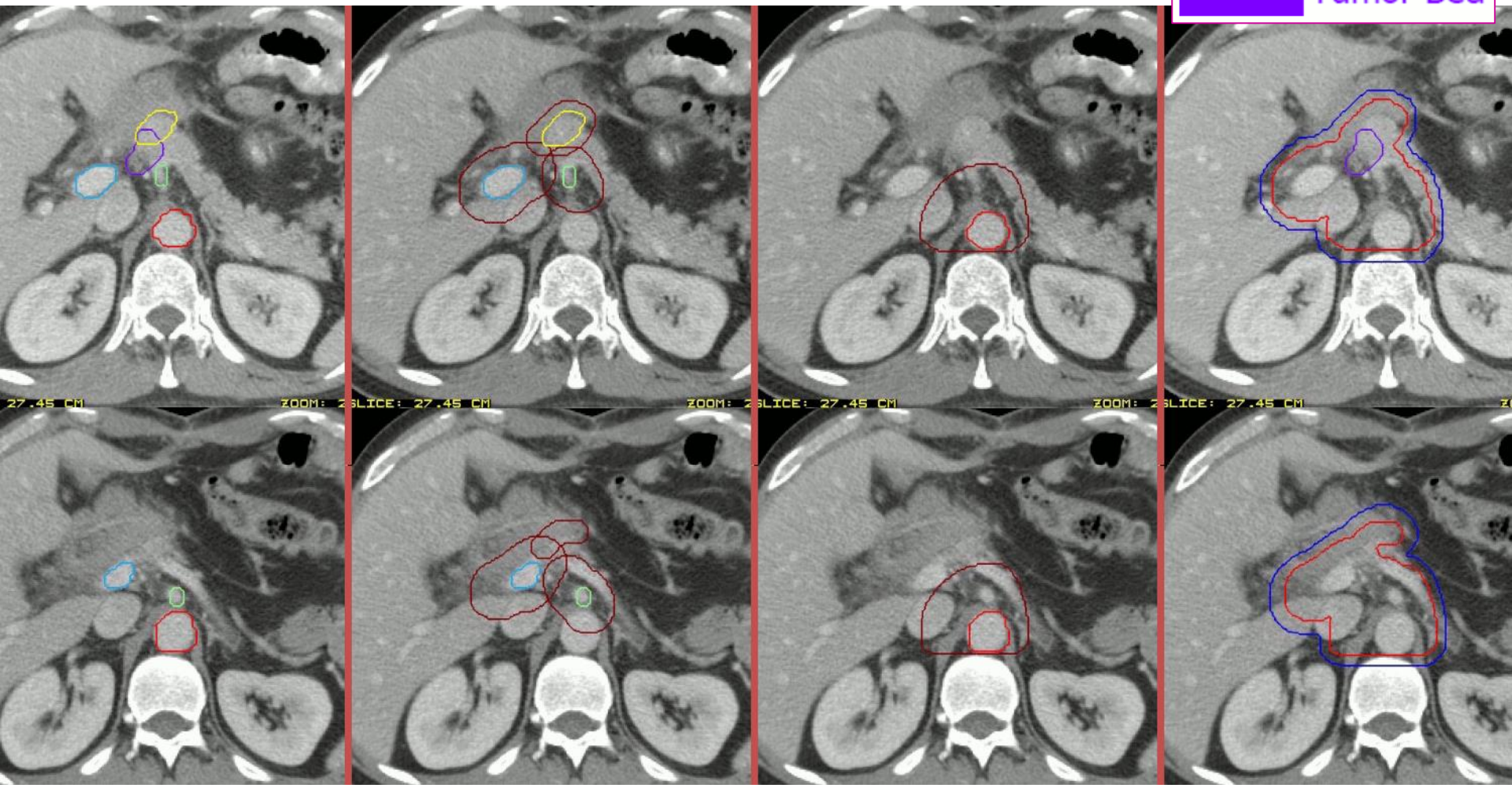

IJROBP 2013, 87, 1007; doi: 10.1016/j.ijrobp.2013.09.005

# Mapping Patterns of Local Recurrence After Pancreaticoduodenectomy for Pancreatic Adenocarcinoma: A New Approach to Adjuvant Radiation Field Design

Avani S. Dholakia, BS,* Rachit Kumar, MD,* Siva P. Raman, MD,†

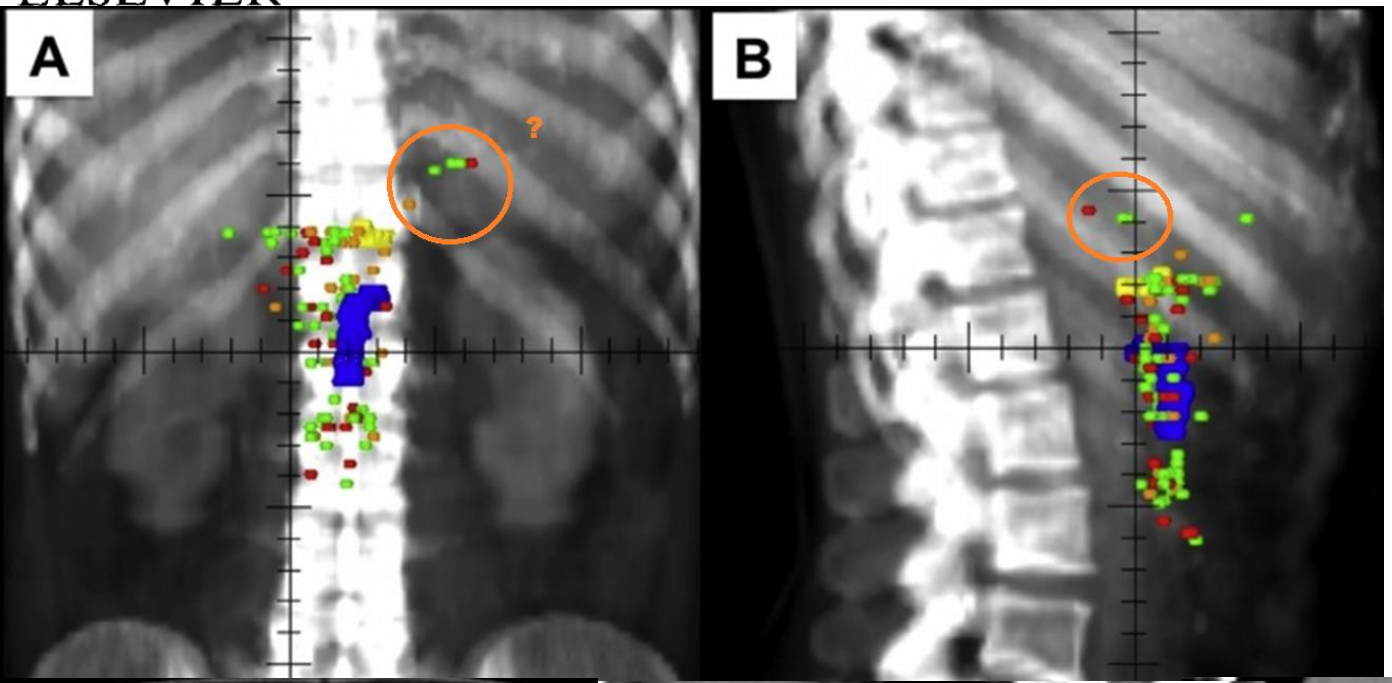


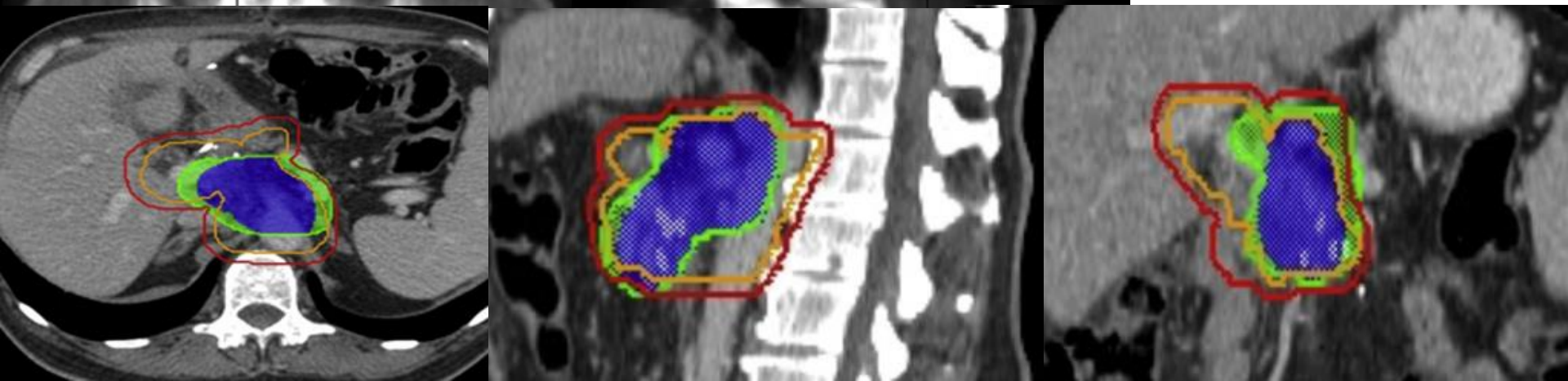

Yu *et al. Radiation Oncology* (2016) 11:138
DOI 10.1186/s13014-016-0714-7

Radiation Oncology

RESEARCH Open Access

# Pancreatic cancer adjuvant radiotherapy target volume design: based on the postoperative local recurrence spatial location

**Results:** Eighty-three patients with local recurrence were included from 305 postoperative pancreatic cancer patients who did not receive adjuvant radiotherapy. Thirty-one (37 %) patients did not have adjuvant therapy at all, 52 (63 %) patients undergone adjuvant chemotherapy alone. Spatial location of local failure was created. Most recurrences occurred near CA or SMA. CTV-90 was generated through expanding the combined SMA and CA contours by 30 mm right-lateral, 21 mm left-lateral, 20 mm anterior, 13 mm posterior, 10 mm superior, and 20 mm inferior. CTV-80, smaller in volume, was also created for simultaneous integrated boost. Through comparison and analysis of the simulated cases, the radiation volumes proposed were much smaller than those with RTOG 0848 contouring consensus guidelines (average volume: PTV-80 = 120 ml, PTV-90 = 220 ml, RTOG PTV = 490 ml). Accordingly, the organs at risk received less irradiation dose with the proposed CTV-90 and CTV-80.

Yu, RadOncol 2016

Lokalizacja nawrotów:

Głowa trzustki

Trzon

Ogon

(CT, SMA)

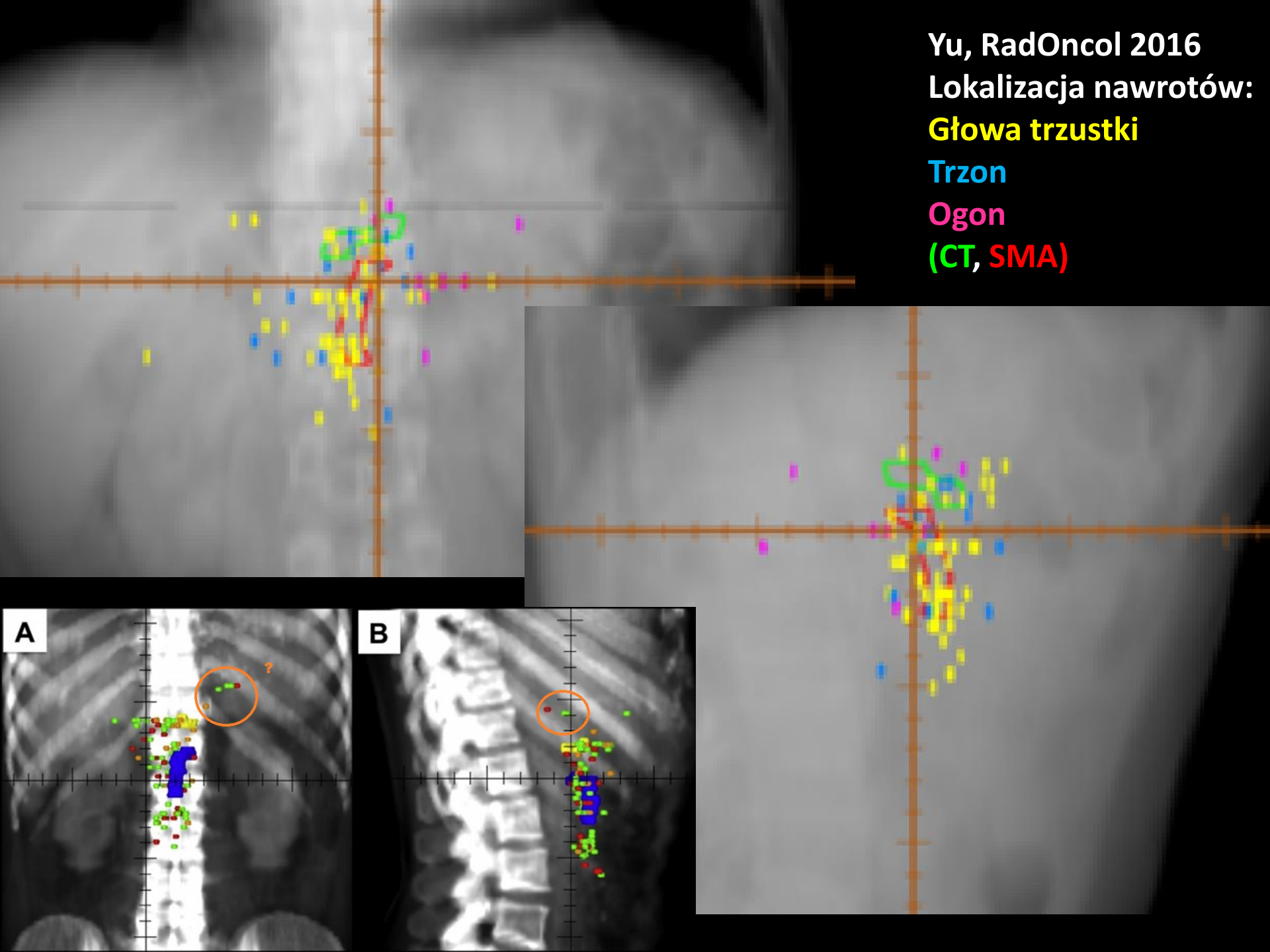

Yu *et al. Radiation Oncology* (2016) 11:138
DOI 10.1186/s13014-016-0714-7

Radiation Oncology

RESEARCH Open Access

# Pancreatic cancer adjuvant radiotherapy target volume design: based on the postoperative local recurrence spatial location

- **rak ogona trzustki – 8 chorych**

**średnia odległość wznowy:**
***od SMA – 36,4mm (19,5mm głowa, 25mm trzon trzustki)**
***od CA – 40,5mm (18,6mm głowa, 12mm trzon trzustki)**
**OBSZAR ELEKTYWNY WYZNACZONY W OPARCIU O SMA I CA JEST NIEADEKWATNY W RAKACH OGONA TRZUSTKI!**

# Układ chłonny trzustki

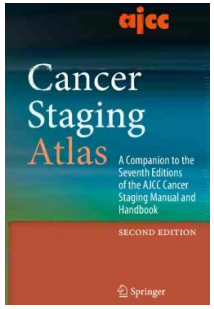


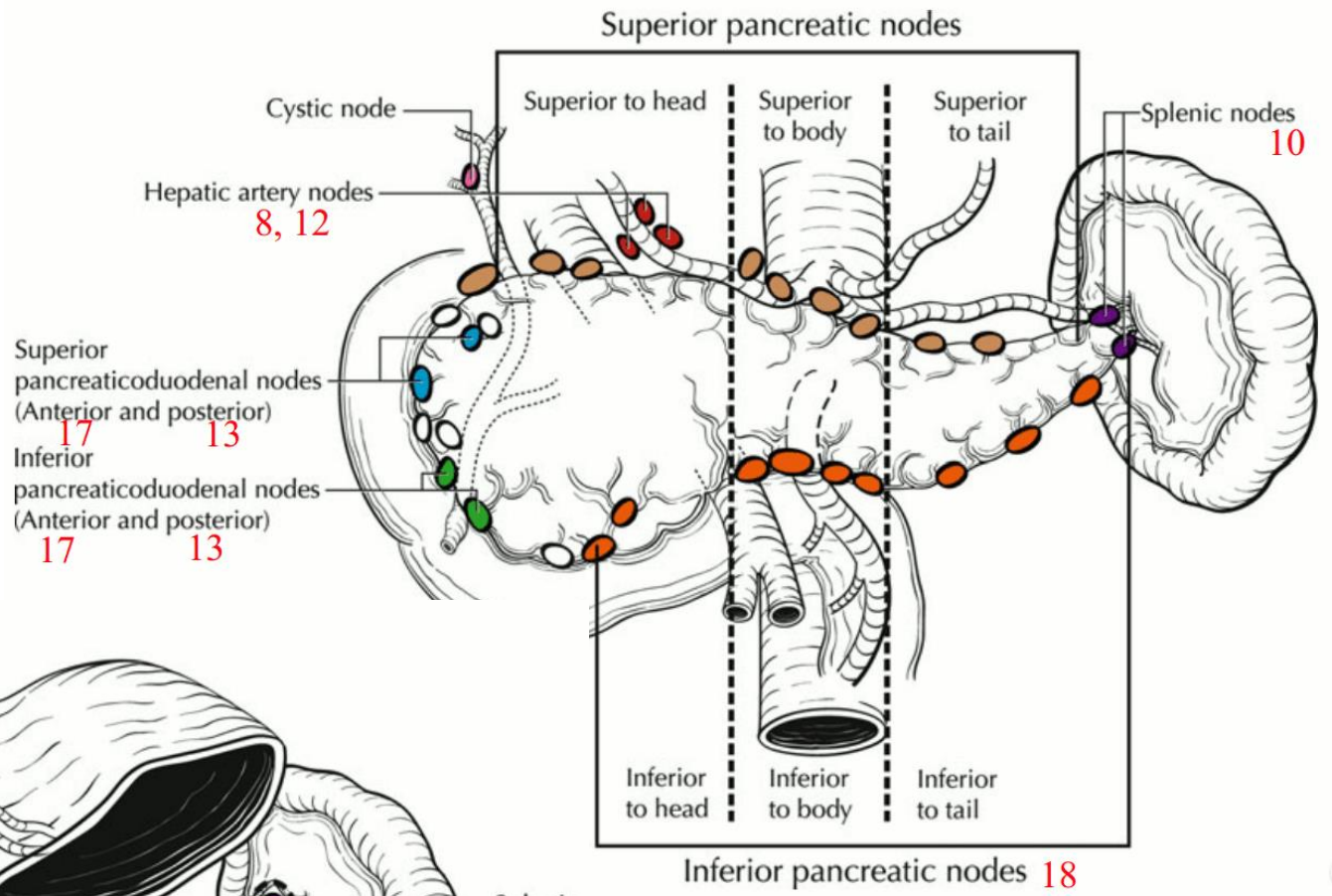


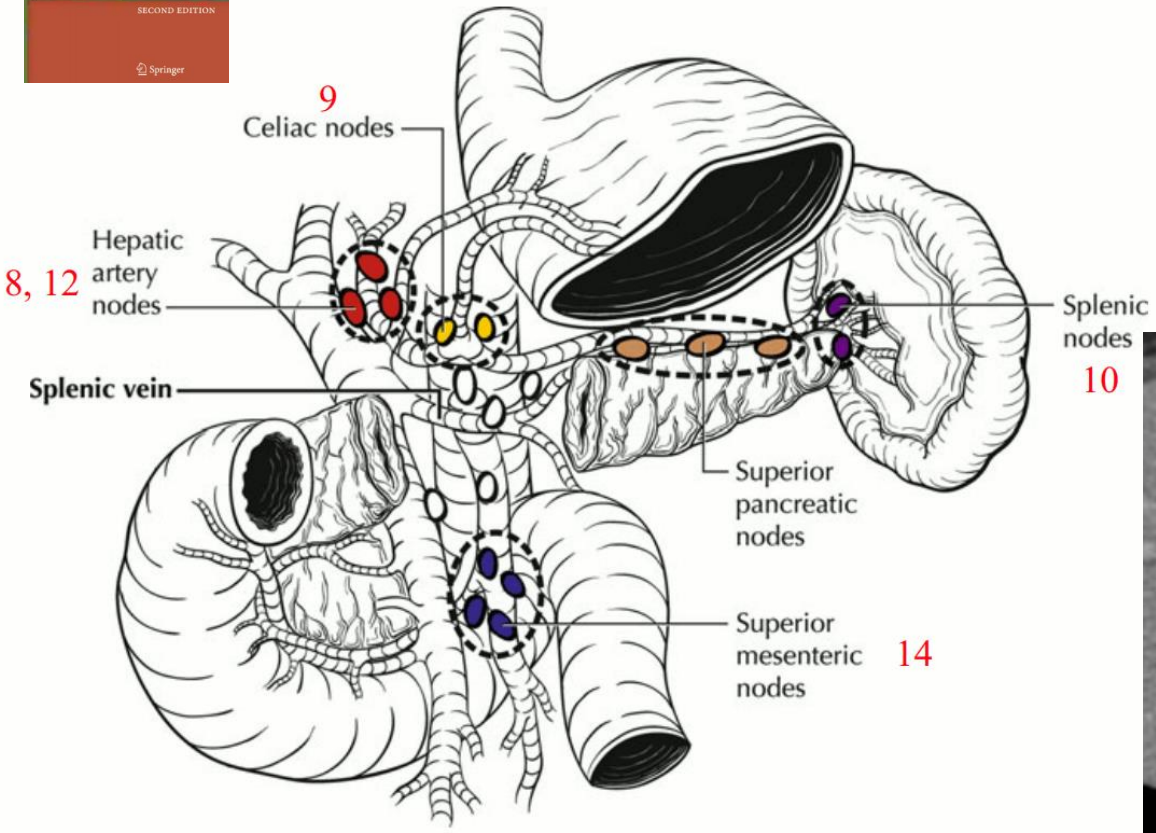


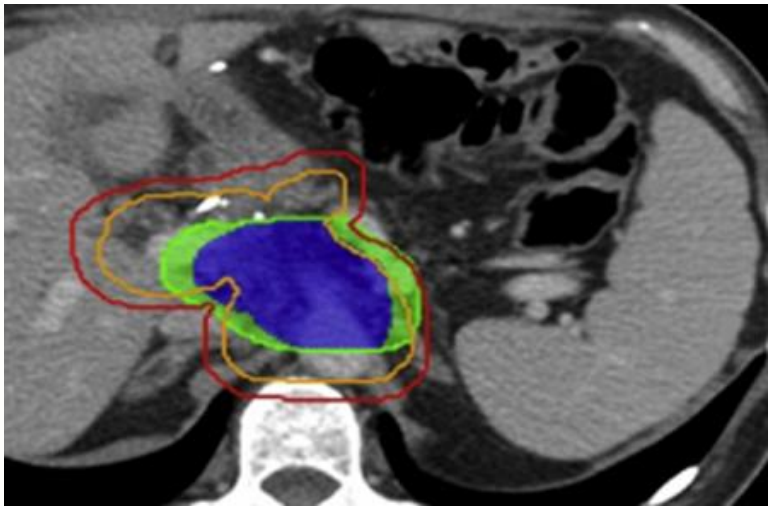

## nCTV - GŁOWA TRZUSTKI

## nCTV - OGON TRZUSTKI

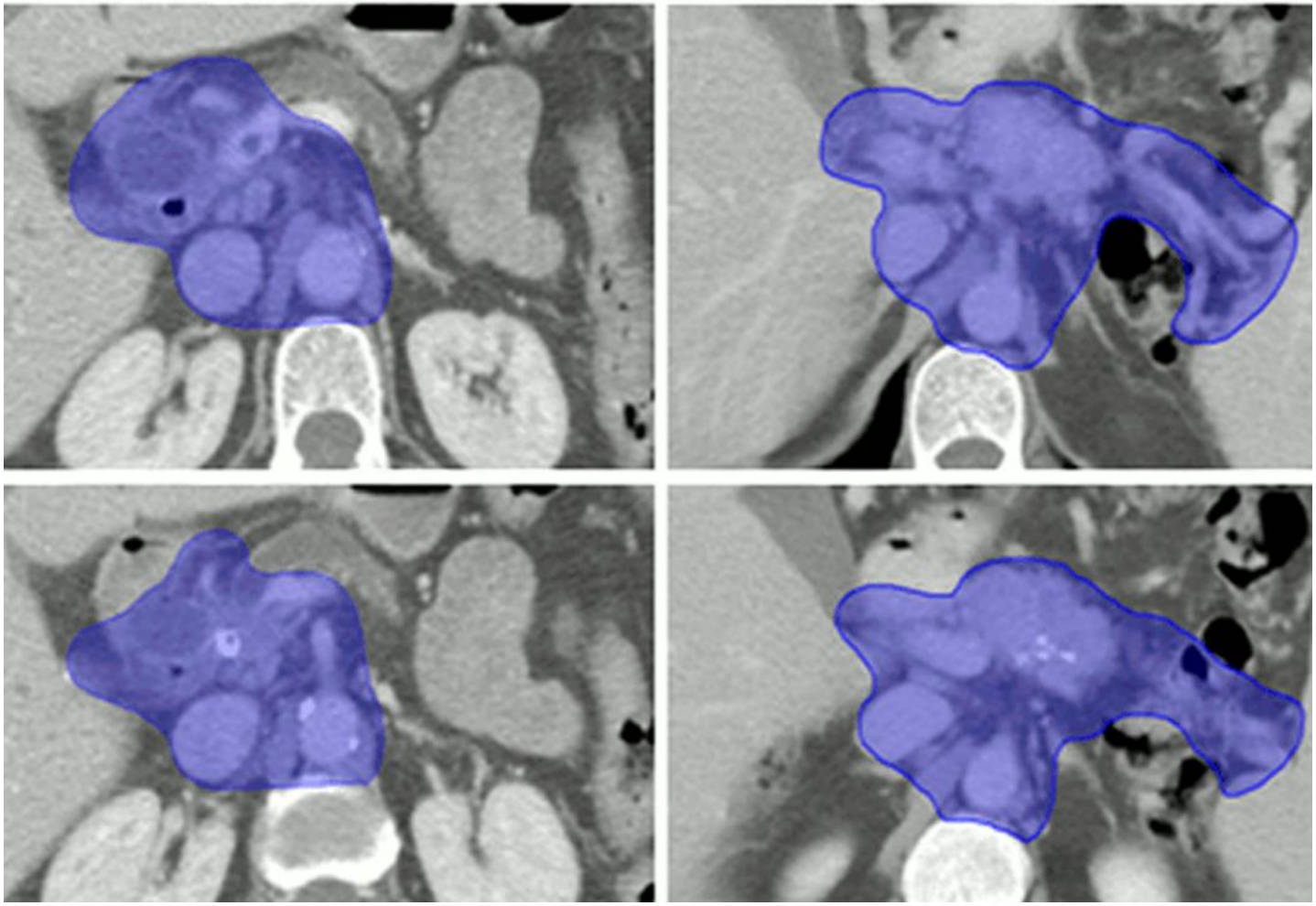

Caravatta, Radiat Oncol 2012

# DZIĘKUJĘ ZA UWAGĘ

jsocha@wim.mil.pl